

From science to practice:

Micro-invasive caries treatment with resin infiltration

In all areas of medicine, there has been a growing shift of focus dedicated to more preventative and early protective therapy options. With the development of its new cutting-edge technology, DMG intends to open up new possibilities within the world of dentistry with “Icon”.

Icon is based on the concept of caries infiltration whose development began at the Charité Berlin (Department of Operative Dentistry and Periodontology, chair: Prof. Dr. A. M. Kielbassa) and was continued at the University of Kiel (Clinic for Operative Dentistry and Periodontology, chair: Prof. Dr. Christoph Dörfer). In close cooperation with the two leading developers OA PD Dr. H. Meyer-Lückel and Dr. Sebastian Paris, DMG developed the means to deliver this new technology, resulting in the product “Icon”.

Since the year 2000, caries infiltration was first examined in vitro and then further developed and tested in the course of in situ and clinical studies. In this brochure you will find an overview of the available results and information on current studies illustrating the clinical efficacy of caries infiltration. To avoid misunderstandings ongoing studies are clearly marked.

We welcome you to see first-hand the many advantages of caries infiltration; whether it be based on the clinical results presented herein or via practical application of this innovative technology.



Dr. Dierk Lübbers
Scientific Affairs Manager

Content

| | |
|--|-----------|
| Micro-invasive caries treatment with resin infiltration | 7 |
| Overview of studies | 8 |
| In vitro studies “caries infiltration” | 12 |
| Improved resin infiltration of natural caries lesions | 13 |
| Resin infiltration of natural caries lesions | 14 |
| Surface layer erosion of natural caries lesions with phosphoric and hydrochloric acid gels in preparation for resin infiltration | 15 |
| Influence of application frequency of an infiltrant on enamel lesions | 16 |
| Penetration coefficients of commercially available and experimental resins intended to infiltrate enamel carious lesions | 17 |
| Infiltration of natural caries lesions with experimental resins differing in penetration coefficients and ethanol addition | 18 |
| Inhibition of progression of natural caries lesions by infiltrants in vitro | 19 |
| Surface conditioning of natural enamel carious lesions in deciduous teeth in preparation for resin infiltration | 20 |
| Influence of different etching gels on the mineral content of initial enamel lesions in primary teeth | 21 |
| Infiltration of natural caries lesions in primary teeth with experimental infiltrants in vitro | 22 |
| Unique treatment of early caries and white spot lesions | 23 |
| Caries infiltration in teeth varying in ICDAS-II codes in vitro | 24 |
| Effect of caries infiltration technique and fluoride therapy on micro-hardness of enamel caries lesions | 25 |
| Infiltration of natural caries lesions with monomer under simulated conditions of the oral cavity | 26 |
| Resin infiltrated artificial caries lesions examined by polarized light microscopy and micro-hardness tests | 27 |
| In vitro color stability of infiltrated caries lesions | 28 |
| Effect of caries infiltration technique and fluoride therapy on the color masking of white spot lesions | 29 |
| Visual assimilation of artificial enamel caries lesions by infiltration in vitro | 30 |
| In vitro resistance of resin infiltrated initial caries lesions (white spots) against tooth brush abrasion | 31 |
| Surface roughness determination of a caries infiltrant resin | 32 |
| Preventing capability of resin-infiltration-technique on occlusal fissures | 33 |
| Influences on bond strength of orthodontic brackets | 34 |
| In vivo studies “caries infiltration” | 36 |
| Caries diagnosis and caries prevention procedures in dental practices in Germany | 37 |
| Progression of infiltrated artificial enamel caries lesions in situ | 38 |
| Effects of application time on infiltrant caries penetration ex vivo | 39 |
| Acceptability of micro-invasive treatment for non-cavitated proximal lesions in children | 40 |
| Resin infiltration of caries lesions: an efficacy randomized trial – 18 months follow-up | 41 |
| Modern detection, assessment and treatment of initial proximal lesions | 42 |
| Progression of active initial-proximal lesions after infiltration, sealing or flossing-instructions | 43 |
| Radiographic comparison of lesion progression after infiltration, sealing and floss instructions in a high caries risk population – 12 and 24 months follow-up | 44 |
| Radiographic progression of infiltrated caries lesions in vivo | 45 |

| | |
|--|-----------|
| Treatment of proximal superficial caries lesions on primary molar teeth with resin infiltration and fluoride varnish versus fluoride varnish only: efficacy after 1 year | 46 |
| Clinical applicability and safety of resin infiltration of proximal caries | 47 |
| The evaluation of resin infiltration for masking labial enamel white spot lesion | 48 |
| Clinical performance and color stability of infiltrated smooth surface lesions (post-orthodontic white spots) | 49 |
| Progression of non-cavitated caries lesions: Efficacy of caries infiltration compared to sealing | 50 |
| Infiltration versus microabrasion for cosmetic treatment of white spot lesion due to orthodontic treatment | 51 |
| Durability of esthetic improvement following white spot lesion treatment with the Icon infiltration system | 52 |
| Infiltration concept – List of literature | 54 |
| Bitewing diagnosis and indications for infiltration | 58 |
| Clinical use – X-ray holder system | 59 |
| Clinical use – proximal surfaces | 60 |
| Clinical use – vestibular surfaces | 61 |
| Hints and tricks for daily practice | 62 |
| Portfolio | 66 |
| Authors | 68 |

Micro-invasive caries treatment with resin infiltration

Meyer-Lückel H, Paris S.

Even if a substantial decrease in caries has been observed in the past decades it still remains one of the most frequent dental diseases. The prevalence of preventive measures has contributed to curbing caries formation. And where this cannot be accomplished modern filling materials facilitate the restoration of cavities on a high medical as well as esthetic level. Unsolved, however, remains an adequate treatment approach for early proximal carious lesions and white spots on smooth surfaces.

Problem area – proximal caries

In today's preventive-oriented dentistry fluoridation measures are aimed at inhibiting the formation of carious lesions. However, as soon as cavitation of the enamel surface is present invasive treatment methods are indicated which involve the removal of relatively large portions of healthy hard tissue. Especially for proximal caries the ratio of the caries and the healthy hard tissue needing to be removed is very unfavorable. Furthermore, due to the aging process of the filler materials the respective restorations must be renewed after varying periods of time.

Sealing as a solution?

An experimental therapy approach for proximal carious lesions is the surface treatment of the demineralized enamel structure with hardening resins similar to fissure sealing in the occlusal region. The objective of this limited invasive therapy is to arrest caries progression in a continuously existing cariogenic environment by obturating the diffusion paths for carbohydrates and organic acids. However, the application of resins in the proximal region can promote the formation of secondary caries due to remaining excess material. And subsequent periodontal irritations would have to be expected as well.

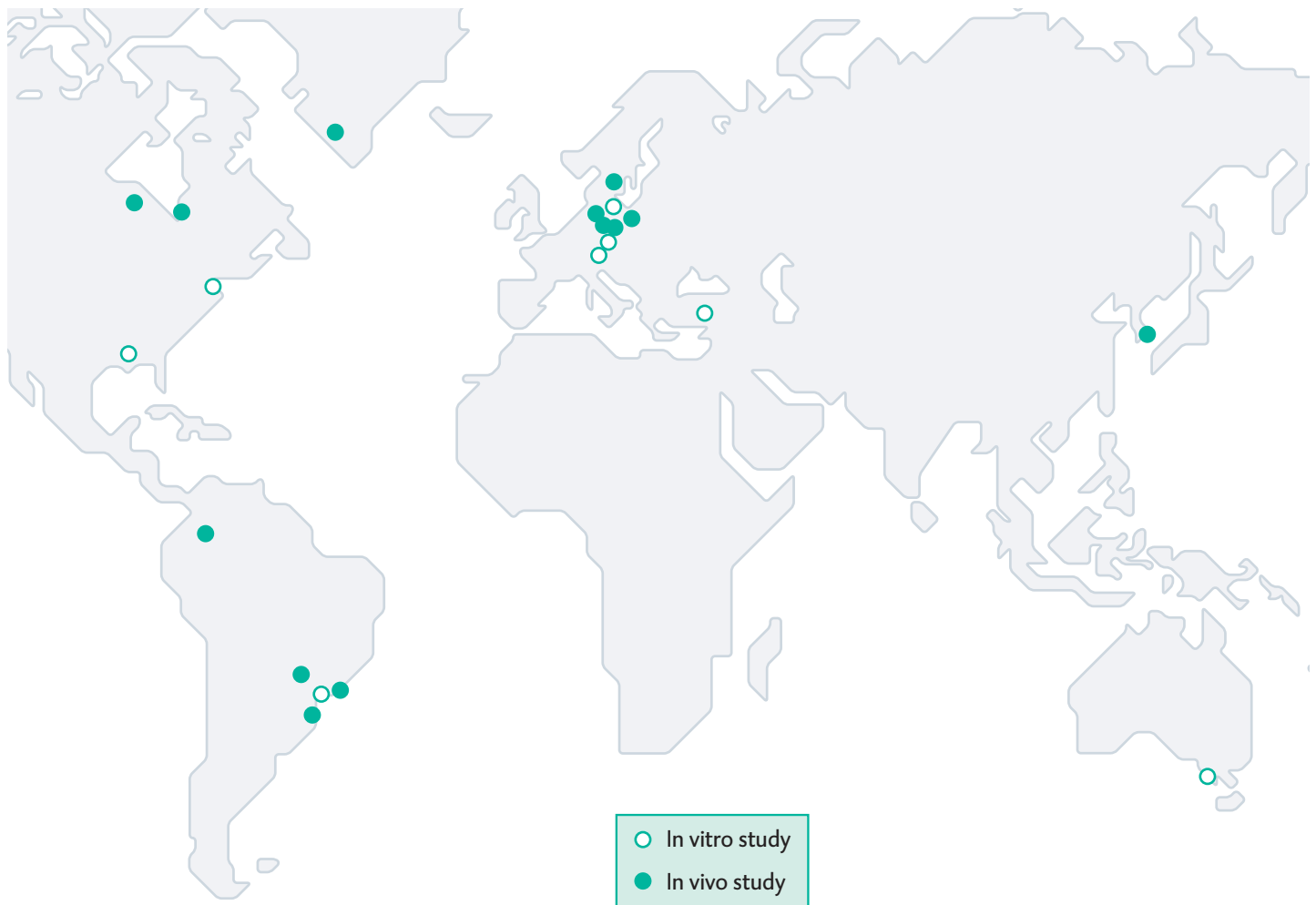
Pioneering solution: infiltration

Based on the described issues of sealing proximal lesions the current approaches to prevent caries progression have been further developed at the Charité in Berlin and the University of Kiel. The promising result: infiltration. For this method the hard tissue lost due to demineralization is replaced even to substantial lesion depths (up to 800 µm) with a low viscosity resin. This micro-invasive treatment method creates a diffusion barrier not on the surface but within the hard tissue thus stabilizing and blocking the caries. For proximal applications caries infiltration is indicated up to a maximum radiological lesion progression into the outer third of the dentine.

Vestibular application

As a positive side effect of the caries infiltration the treated enamel lesions lose their whitish opaque color and resemble healthy enamel more than untreated white spots. Thus, caries infiltration constitutes a much gentler treatment alternative for vestibular smooth surface lesions which are frequently observed after the removal of fixed orthodontic appliances and in patients with poor oral hygiene. This method therefore allows for a drastic improvement of the esthetic appearance of such lesions and a long-term caries arrest in only one visit.

Overview of studies



| No. | Title | Principal Investigator | University |
|-----|---|---|--|
| ① | Development of the infiltration technique ¹ (pages 13 – 22) | Meyer-Lückel, H. Paris, S. | Charité – Universitätsmedizin Berlin, Berlin, Germany Christian-Albrechts-Universität, Kiel, Germany |
| ② | Unique treatment of early caries and white spot lesions ² | Nobrega, D. Perry, R. | Tufts University, Boston, MA, USA |
| ③ | Caries infiltration in teeth varying in ICDAS-II codes in vitro ² | Meyer-Lückel, H. Paris, S. | Christian-Albrechts-Universität, Kiel, Germany |
| ④ | Effect of caries infiltration technique and fluoride therapy on micro-hardness of enamel caries lesions ² | Rocha Gomes Torres, C. Bühler Borges, A. | Universidade Estadual Paulista (UNESP), São José dos Campos, SP, Brazil |
| ⑤ | Infiltration of natural caries lesions with monomer under simulated conditions of the oral cavity ² | Schneider, H. | University of Leipzig, Leipzig, Germany |
| ⑥ | Resin infiltrated artificial caries lesions examined by polarized light microscopy and micro-hardness tests ² | Palamara, J. | The University of Melbourne, Melbourne, VIC, Australia |
| ⑦ | In vitro color stability of infiltrated caries lesions ² | Lübbers, D. Staude, C. | DMG, Dental-Material Gesellschaft mbH, Hamburg, Germany |

| No. | Title | Principal Investigator | University |
|-----|---|---|---|
| 8 | Effect of caries infiltration technique and fluoride therapy on the color masking of white spot lesions ² | Rocha Gomes Torres, C. Bühler Borges, A. | Universidade Estadual Paulista (UNESP), São José dos Campos, SP, Brazil |
| 9 | Visual assimilation of artificial enamel caries lesions by infiltration in vitro ² | Paris, S. Meyer-Lückel, H. | Christian-Albrechts-Universität, Kiel, Germany |
| 10 | In vitro resistance of resin infiltrated initial caries lesions (white spots) against tooth brush abrasion ² | Lohbauer, U. Schubert, EW. | University of Erlangen-Nuremberg, Erlangen, Germany |
| 11 | Surface roughness determination of a caries infiltrant resin ² | Burgess, JO. | University of Alabama, Birmingham, AL, USA |
| 12 | Preventing capability of resin-infiltration-technique on occlusal fissures ² | Gurgan, S. Firat, E. | Hacettepe University, Ankara, Turkey |
| 13 | Influences on bond strength of orthodontic brackets ² | Phark, JH. Duarte, S. | Case Western Reserve University, Cleveland, OH, USA University of Southern California, Los Angeles, CA, USA |
| 14 | Caries diagnosis and caries prevention procedures in dental practices in Germany ¹ | Lawrenz, MC. Schiffner, U. | University of Hamburg, Hamburg, Germany |
| 15 | Progression of infiltrated artificial enamel caries lesions in situ ² | Paris, S. Meyer-Lückel, H. | Charité – Universitätsmedizin Berlin, Berlin, Germany Christian-Albrechts-Universität, Kiel, Germany |
| 16 | Effects of application time on infiltrant caries penetration ex vivo ² | Mendes Soviero, V. | Universidade do Estado do Rio de Janeiro (UERJ), Rio de Janeiro, RJ, Brazil |
| 17 | Acceptability of micro-invasive treatment for non-cavitated proximal lesions in children ² | Mendes Soviero, V. Garcia dos Santos, M. | Universidade do Estado do Rio de Janeiro (UERJ), Rio de Janeiro, RJ, Brazil Universidade de São Paulo (USP), São Paulo, SP, Brazil |
| 18 | Resin infiltration of caries lesions: an efficacy randomized trial – 18 months follow-up ² | Paris, S. Meyer-Lückel, H. | Charité – Universitätsmedizin Berlin, Berlin, Germany Christian-Albrechts-Universität, Kiel, Germany |
| 19 | Modern detection, assessment and treatment of initial proximal lesions ¹ | Martignon, S. Paris, S. | Universidad El Bosque, Bogotá, Colombia Christian-Albrechts-Universität, Kiel, Germany |
| 20 | Progression of active initial-proximal lesions after infiltration, sealing or flossing-instructions ² | Martignon, S. Ekstrand, KR. | Universidad El Bosque, Bogotá, Colombia University of Copenhagen, Copenhagen, Denmark |
| 21 | Radiographic comparison of lesion progression after infiltration, sealing and floss instructions in a high risk caries population – 12 and 24 months follow-up ² | Martignon, S. Ekstrand, KR. | Universidad El Bosque, Bogotá, Colombia University of Copenhagen, Copenhagen, Denmark |
| 22 | Radiographic progression of infiltrated caries lesions in vivo ² | Peters, MC. | University of Michigan, Ann Arbor, MI, USA The University of Toledo, Toledo, OH, USA |
| 23 | Treatment of proximal superficial caries lesions on primary molar teeth with resin infiltration and fluoride varnish versus fluoride varnish only: efficacy after 1 year ² | Ekstrand, KR. Bakshandeh, A. | University of Copenhagen, Copenhagen, Denmark |
| 24 | Clinical applicability and safety of resin infiltration of proximal caries ² | Alkilzy, M. Splieth, CH. | Ernst-Moritz-Arndt-Universität, Greifswald, Germany |
| 25 | The evaluation of resin infiltration for masking labial enamel white spot lesions ² | Kim, S. | Pusan National University, Pusan, Korea |
| 26 | Clinical performance and color stability of infiltrated smooth surface lesions (post-orthodontic white-spots) ² | Phark, JH. Duarte, S. | Case Western Reserve University, Cleveland, OH, USA |
| 27 | Progression of non-cavitated caries lesions: Efficacy of caries infiltration compared to sealing ² | Anauate-Netto, C. | Universidade dos Bandeirantes (UNIBAN), São Paulo, SP, Brazil |
| 28 | Infiltration versus microabrasion for cosmetic treatment of white spot lesion due to orthodontic treatment ² | Coelho Leal, S. Ekstrand, KR. | Universidade de Brasília (UnB), Brasília, DF, Brazil University of Copenhagen, Copenhagen, Denmark |
| 29 | Durability of esthetic improvement following white spot lesion treatment with the Icon infiltration system ² | Knösel, M. | Georg-August-Universität, Göttingen, Germany |

In vitro studies

In vitro studies “caries infiltration”

Sealing or infiltrating proximal and buccal lesions with resins might be a promising strategy to hamper further demineralization of carious lesions. Penetration abilities of commercially available adhesives have been studied priorly to the start of the present development using in vitro lesions. At first, visualization methods using confocal microscopy (CLSM) were developed to study penetration depths of the resins and the according lesion depths simultaneously. Lesion depth measurements were correlated with those of the gold standard (transversal microradiography). Subsequently, penetrating and caries inhibiting abilities of various commercially available adhesives were evaluated using in vitro lesions.

To develop improved materials penetration coefficients (PC) of experimental monomer mixtures were determined. Subsequently, penetrating as well as caries inhibiting properties of these materials were compared using in vitro lesions.

Due to the compact surface layers of natural lesions resin penetration was shown to be hampered. Therefore, an etching procedure to erode the surface layer of these lesions was developed. Natural lesions etched with hydrochloric acid (15 %) for at least 90 s showed a reliable erosion of the surface that allowed improved penetration of the investigated adhesive. Subsequently, penetration depths of adhesives were compared with those of an infiltrant (PC > 50 cm/s). The validated measurements with CLSM revealed differences in penetration depths as well as the inhibition of lesion progression between several adhesives. Superior abilities to penetrate artificial lesions and to hamper lesion progression were observed for infiltrants compared to adhesives. Moreover, an experimental infiltrant revealed higher penetration depths than the adhesive. Clinical application to proximal surfaces could be accomplished by using separation and application tools developed for this purpose. On the basis of these promising preclinical results the clinical implementation of this so called micro-invasive therapy is advisable.

Improved resin infiltration of natural caries lesions

Meyer-Lückel H, Paris S.

Department of Operative Dentistry and Periodontology, Christian-Albrechts-Universität, Kiel, Germany

Objectives

In artificial lesions improved penetration and caries-inhibiting properties of infiltrating resins could be observed with increasing penetration coefficients (PCs). The aim of the present study was to compare the penetration abilities of an experimental 'infiltrant' into natural lesions with those of an adhesive in vitro.

Methods

Corresponding lesion halves of extracted human molars and premolars showing proximal white spot lesions (ICDAS: code 2) were etched for 120 sec with 15 % hydrochloric acid gel and subsequently treated with either an adhesive (PC: 31 cm/sec) or an infiltrant (PC: 273 cm/sec) (n = 64). Excess material was removed before light curing. Teeth were sectioned perpendicular to the lesion surfaces and lesion pores were stained with fluorescein solution. Specimens were observed by confocal microscopy (CLSM) and transverse microradiography.

Results

Penetration depths of the adhesive were significantly lower compared with those of the infiltrant ($p < 0.001$; Wilcoxon).

Conclusion

Resins with higher PCs (infiltrants) show superior ability to penetrate natural lesions compared with resins with lower PCs.

This study was supported by the Deutsche Forschungsgemeinschaft (DFG; PA 1508/1-1).

Source:

Meyer-Lückel H, Paris S. Improved resin infiltration of natural caries lesions. J Dent Res 2008;87:1112-1116

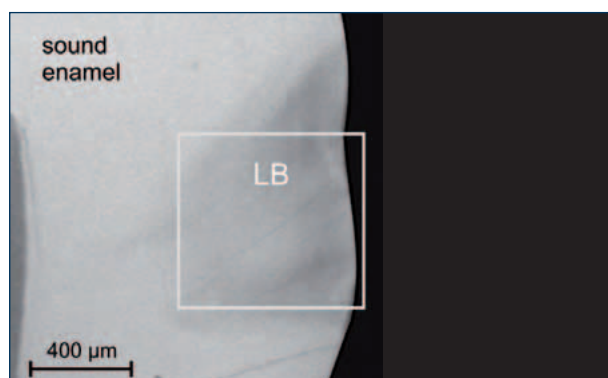

Illustration 1: Microradiographic image of a natural caries lesion (LB = lesion body).




Illustration 2: In the CLSM image the infiltrant (I) was displayed in red or grayish color.

Resin infiltration of natural caries lesions

Paris S, Meyer-Lückel H, Kielbassa AM.

Department of Operative Dentistry and Periodontology, Charité – Universitätsmedizin Berlin, Berlin, Germany

Objectives

Infiltration of non-cavitated caries lesions with light-curing resins could lead to an arrest of lesion progression. The aim of this study was to evaluate the penetration of a conventional adhesive into natural enamel caries after pre-treatment with two different etching gels in vitro.

Methods

Extracted human molars and premolars showing proximal white spot lesions were cut across the lesions perpendicular to the surface. Corresponding lesion halves were etched for 120 sec with either 37 % phosphoric acid gel (H_3PO_4) or 15 % hydrochloric acid gel (HCl), and subsequently infiltrated with an adhesive. Specimens were observed by confocal microscopy.

Results

Mean penetration depths (SD) in the HCl group [58 (37) μm] were significantly increased compared with those of the H_3PO_4 group [18 (11) μm] ($p < 0.001$; Wilcoxon).

Conclusion

It can be concluded that etching with 15 % hydrochloric acid gel is more suitable than 37 % phosphoric acid gel as a pre-treatment for caries lesions intended to be infiltrated.

Source:

Paris S, Meyer-Lueckel H, Kielbassa AM. Resin infiltration of natural caries lesions. J Dent Res 2007, 86(7):662-6

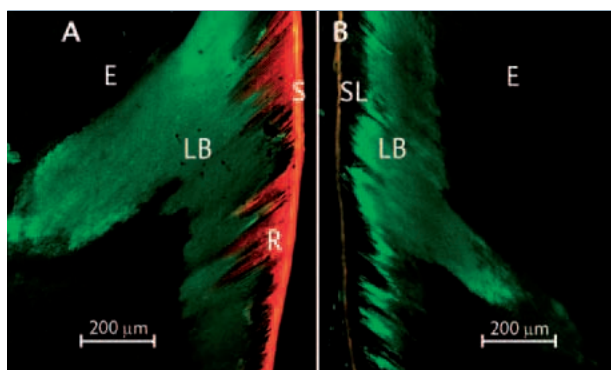


Illustration 1: Resin penetration into natural caries lesions after different erosion procedures. A: Deep resin penetration after etching with HCl. B: Incomplete removal of the surface layer after etching with H_3PO_4 results in very superficial resin penetration. (E = sound enamel, LB = lesion body, R = penetrated resin, S = lesion surface, SL = pseudointact surface layer)

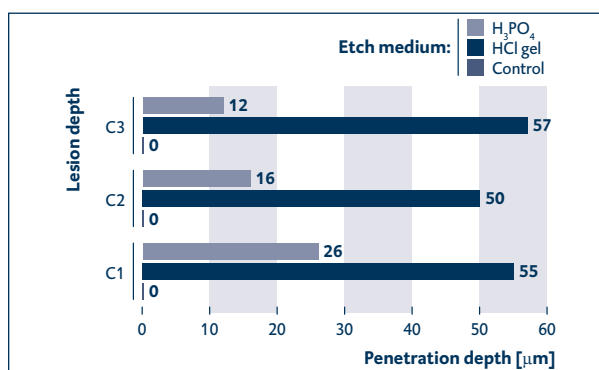


Illustration 2: Mean penetration depths of resin for various pre-treatments and histological lesion extensions (box and whisker plots with quartiles and medians, $n = 10$ per group). (C1 = caries extension into the outer half of enamel, C2 = caries extension into the inner half of enamel, C3 = caries extension into the outer half of dentin)

Surface layer erosion of natural caries lesions with phosphoric and hydrochloric acid gels in preparation for resin infiltration

Meyer-Lückel H, Paris S, Kielbassa AM.

Department of Operative Dentistry and Periodontology, Charité – Universitätsmedizin Berlin, Berlin, Germany

Objectives

The infiltration of proximal enamel lesions with low-viscosity light curing resins could be a viable approach to stop lesion progression. However, penetration of sealant might be hampered by the comparatively highly mineralized surface layers of natural lesions.

Therefore, the aim of this study was to compare the efficacy of three different etching gels in removing the surface layer in various etching times.

Methods

Extracted human molars and premolars showing proximal white spot lesions were cut across the demineralized areas. Ninety-six lesions expected from visual examination to be confined to the outer enamel (C1) were selected. The cut surface and half of each lesion were varnished, thus serving as control. Subsequently, the lesions were etched with either phosphoric (37 %) or hydrochloric (5 or 15 %) acid gel for 30–120 s ($n=8/\text{group}$). Specimens were examined using confocal microscopy and transversal microradiography.

Results

Surface layer reduction was significantly increased in lesions etched with 15 % HCl gel for 90 and 120 s compared to those etched with H_3PO_4 gel for 30–120 s ($p < 0.05$). No significant differences regarding the depths of erosion in the lesions compared to sound enamel could be observed ($p > 0.05$).

Conclusion

An effective reduction in the surface layer of natural enamel caries can be achieved by etching with 15 % hydrochloric acid gel for 90–120 s.

Source:

Meyer-Lueckel H, Paris S, Kielbassa AM. Surface layer erosion of natural caries lesions with phosphoric and hydrochloric acid gels in preparation for resin infiltration. *Caries Res* 2007, 41(3):223-30




Illustration 1: CLSM image of acid-etched and protected lesion surfaces. The surface layer thickness was measured in the etched (SLE) lesion surfaces as well as in the unetched control (SLC). In lesions etched with 15 % HCl gel for 120 s, a complete erosion of the surface layer (EL) was accomplished.

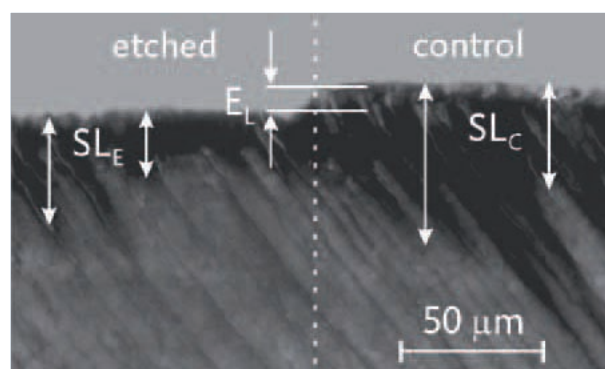


Illustration 2: CLSM image of acid-etched and protected lesion surfaces. The surface layer thickness was measured in the etched (SLE) lesion surfaces as well as in the unetched control (SLC). In lesions etched with 37 % H_3PO_4 for 30 s, only slight erosions of the surface layers (EL) could be observed.

Influence of application frequency of an infiltrant on enamel lesions

Paris S^{1,2}, Meyer-Lückel H^{1,2}.

¹Department of Operative Dentistry and Periodontology, Charité – Universitätsmedizin Berlin, Berlin, Germany

²Department of Operative Dentistry and Periodontology, Christian-Albrechts-Universität, Kiel, Germany

Objectives

The aim of this study was to evaluate the application frequency of two experimental low viscous resins (infiltrants) on lesion progression and micro hardness of resin infiltrated artificial enamel lesions in vitro.

Methods

Twenty-six bovine enamel specimens were demineralized (pH 4.95; 50 days) to prepare three windows of caries-like lesions. Two of these windows were etched with phosphoric acid (37 %) for 5 s, the third one served as control. Both etched lesion parts were treated with either one of two infiltrants (A: BisGMA 25 %, TEGDMA 75 %; B: BisGMA 20 %, TEGDMA 60 %, ethanol 20 %). The respective infiltrant was applied onto both windows (10 s), excessive material was removed and the material light cured (60 s). This procedure was repeated on one of the two windows of each specimen. Subsequently, lesions were cut in two halves, one being stored in the demineralizing solution for another 50 days, the other serving as baseline control. Lesion depths and mineral losses were evaluated by microradiography (n=13). Vickers hardness numbers (VHN) were assessed on cut surfaces 50 µm below the surface (n=9).

Results

Control lesions of the baseline halves showed a mean (SD) mineral loss of 15.205 (1.820) vol. %×µm and a lesion depth of 357 (32) µm. Irrespective of the material control lesions as well as those being infiltrated once progressed significantly (t-test, $p < 0.05$), whereas those being infiltrated twice revealed no significant progression ($p > 0.05$). Lesions being infiltrated twice [48 (17)] showed significantly higher VHN compared with those being infiltrated once [37 (16)], which were again significantly higher than those of the control lesions [7 (5)] ($p < 0.05$). No significant differences in micro hardness could be observed between the materials ($p > 0.05$).

Conclusion

Twice infiltration results in a hampered lesion progression and a gain in micro hardness in artificial lesions. This study was supported by Deutsche Forschungsgemeinschaft (PA 1508/1-1).

Source:

Paris S, Meyer-Lueckel H. Influence of application frequency of an infiltrant on enamel lesions. J Dent Res 2008, (Spec Iss B):1585

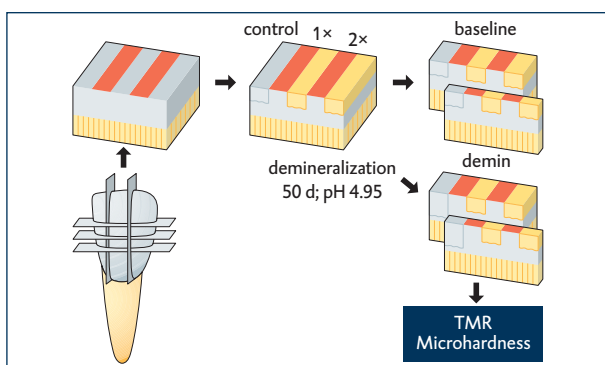


Illustration 1: Specimen preparation.




Illustration 2: Progression of lesion depths after one and two fold infiltration.

Penetration coefficients of commercially available and experimental resins intended to infiltrate enamel carious lesions

Paris S¹, Meyer-Lückel H¹, Cölfen H², Kielbassa AM¹.

¹Department of Operative Dentistry and Periodontology, Charité – Universitätsmedizin Berlin, Berlin, Germany

²Department of Colloid Chemistry, Max-Planck-Institute of Colloids and Interfaces, Potsdam-Golm, Germany

Objectives

Arresting of enamel lesions by infiltration with light-curing resins might be a treatment alternative of future micro-invasive dentistry. So far only commercially available adhesives and fissure sealants have been used to infiltrate enamel lesions. Since these products have been optimized for adhesive purposes, the aim of this study was to develop optimized resins for the infiltration of enamel lesions and to measure their physical properties.

Methods

The penetration coefficients (PCs) of five adhesives and a fissure sealant as well as 66 experimental composite resins were determined. To establish the resins' PCs the viscosities, surface tensions and contact angles to bovine enamel were measured.

Results

For the commercially available products PCs from 4.0 to 278.9 cm/s were measured. Four of these materials showed a good correlation with penetration depths obtained in a previous study. Experimental resins showed PCs from 0.2 to 474.9 cm/s. The addition of ethanol significantly increased the PCs due to a decrease of viscosity and contact angle. Highest PCs were found for mixtures containing TEGDMA, HEMA and 20 % ethanol.

Conclusion

The knowledge about the PC of resins seems to be useful for the development of new materials optimized to infiltrate enamel lesions.

Source:

Paris S, Meyer-Lueckel H, Cölfen H, Kielbassa AM. Penetration coefficients of commercially available and experimental composites intended to infiltrate enamel carious lesions. *Dent Mater* 2007, 23(6):742-8

Infiltration of natural caries lesions with experimental resins differing in penetration coefficients and ethanol addition

Meyer-Lückel H, Paris S.

Department of Operative Dentistry and Periodontology, Christian-Albrechts-Universität, Kiel, Germany

Objectives

Resin infiltration of enamel caries lesions requires materials optimized for penetration into the capillary structures of the lesion body. With increasing penetration coefficients (PC) improved penetration and caries-inhibiting properties of low-viscosity resins (infiltrants) could be observed in artificial caries lesions. The aim of the present in vitro study was to compare the penetrativity of experimental resins varying in PC and ethanol addition into natural caries lesions using this technique.

Methods

Extracted human molars and premolars showing proximal white spot lesions (ICDAS: code 2) were etched for 2 min using 15 % hydrochloric acid gel. After drying, lesions were stained with tetramethylrhodamine isothiocyanate and either one of four experimental resins (PC63; PC185; PC204; PC391) was applied for 5 min. Materials consisted of bisphenol-A-glycidyl-methacrylate (B), tri-ethylene-glycol-dimethacrylate (T), and ethanol (E) in ratios (B:T:E) of PC63: 25:75:0; PC185: 20:60:20; PC204: 0:100:0; PC391: 0:80:20. Excess material was removed before light curing. Teeth were sectioned perpendicular to the lesion surfaces and unbound dye was bleached by immersion in hydrogen peroxide. Remaining lesion pores were stained with fluorescein solution. Lesion and penetration depths were analyzed using confocal microscopy (n = 60).

Results

At deep lesion sites percentage penetration of PC204 was significantly higher compared to PC63 and PC391 ($p < 0.05$; Mann-Whitney test), but only slightly higher than PC185 ($p > 0.05$) (ill. 1). Only PC204 penetrated the caries lesions nearly completely in all cases (ill. 2).

Conclusion

It can be concluded that materials with high penetration coefficients (infiltrants) are capable to penetrate almost completely into enamel parts of natural caries lesions in vitro. A solvent-free resin mainly consisting of TEGDMA seems to be preferable.

This study was supported by the Deutsche Forschungsgemeinschaft (DFG; PA 1508/1-1).

Source:

Meyer-Lückel H, Paris S. Infiltration of natural lesions with experimental resins differing in penetration coefficients and ethanol addition. *Caries Res* 2010;44:408-414

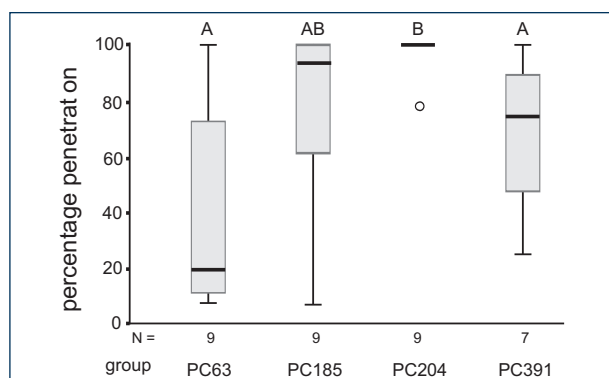


Illustration 1: Box plots of the percentage penetration (PP) of the four materials into caries lesions with LDmax > 500 μ m.

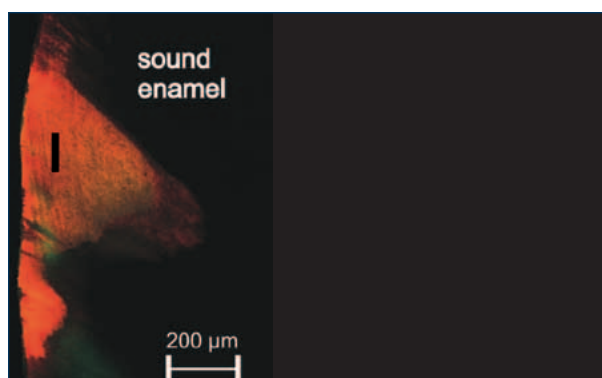


Illustration 2: Representative confocal laser scanning microscope images of enamel caries lesion almost completely infiltrated (I) with PC204 (the later infiltrant).

Inhibition of progression of natural caries lesions by infiltrants in vitro

Paris S, Meyer-Lückel H.

Department of Operative Dentistry and Periodontology, Christian-Albrechts-Universität, Kiel, Germany

Objectives

The aim of this study was to evaluate the progression of infiltrated natural enamel caries lesions stored in a demineralizing environment in vitro.

Methods

Natural enamel caries lesions (ICDAS: code 2) of extracted teeth were etched with 15 % hydrochloric acid gel for 2 min and subsequently infiltrated with either one of four experimental infiltrants (A: BisGMA 25 %, TEGDMA 75 %; B: BisGMA 20 %, TEGDMA 60 %, ethanol 20 %; C: TEGDMA 100 %; D: TEGDMA 80 %, ethanol 20 %) for 5 min. As a positive control lesions were covered with a flowable composite resin after etching and bonding, whereas untreated lesions served as negative controls. Specimens were exposed to a demineralizing solution (pH 4.95) for 400d. Progression of lesion depths and mineral losses were analyzed using Transversal Wavelength Independent Microradiography.

Results

Percentage progressions of NegC [median (25th/75th percentile), 24 (10/56)], PC63 [9 (3/39)], and PC185 [12 (9/24)] were significantly higher compared to PosC [1 (-8/8)], PC204 [-2 (-4/2)], and PC391 [0 (-5/9)] ($p < 0.05$).

Conclusion

Compared to untreated lesions, infiltrated natural enamel caries lesions show lower progression rates in a demineralizing environment in vitro. Materials with high penetration coefficients (infiltrants) were capable to inhibit lesion progression completely.

This study was supported by the Deutsche Forschungsgemeinschaft (DFG; PA 1508/1-1).

Source:

Paris S, Meyer-Lückel H. Inhibition of progression of natural caries lesions by infiltrants in vitro. J Dent Res 2010;89:1276-1280




Illustration 1: Representative transversal wavelength-independent microradiographic image.

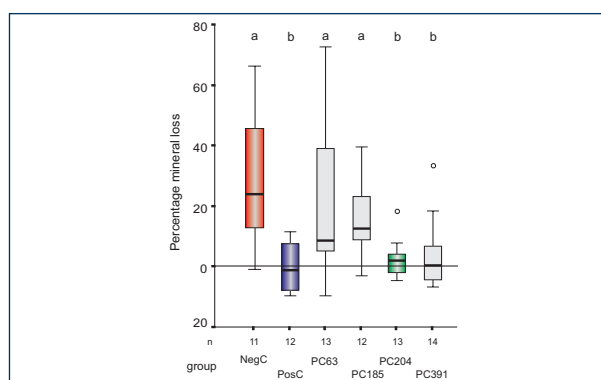


Illustration 2: Box plots of percentage changes in mineral loss of negative and positive control as well as of those lesions treated with the four resins (green box: infiltrant) after 400 days demineralization compared with baseline.

Surface conditioning of natural enamel carious lesions in deciduous teeth in preparation for resin infiltration

Paris S, Dörfer CE, Meyer-Lückel H.

Department of Operative Dentistry and Periodontology, Christian-Albrechts-Universität, Kiel, Germany

Objectives

Resin infiltration of enamel caries is a promising approach for arresting lesion progression. However, the relatively impermeable surface layer of natural enamel lesions hampers resin penetration into the lesion body and should thus be removed before infiltration. For permanent teeth hydrochloric acid has been shown to be suitable for surface layer erosion. Due to structural differences (e.g. aprismatic layer) between permanent and primary teeth, it is unclear whether this etching regimen can be transferred to the deciduous dentition. The aim of the present study was to evaluate the effect of etching the surface layer of natural white spot lesions in primary teeth using phosphoric and hydrochloric acid gels.

Methods

Extracted or exfoliated primary molars showing proximal white spot lesions were cut perpendicularly to the surface across the demineralizations and lesions confined to enamel were selected. The cut surfaces as well as parts of the lesions surfaces were varnished (control). Subsequently, corresponding lesion halves were etched with either 37 % phosphoric or 15 % hydrochloric acid gel for 30, 60, 90, and 120 s, respectively ($n = 9$). Specimens were observed using confocal microscopy and surface layer thicknesses in etched and protected lesion parts as well as erosion depths were measured.

Results

Etching with H_3PO_4 resulted in incomplete reduction of the surface layers in all groups [highest percentage reduction (SD) at 120 s: 54 (28) %]. In contrast, surface layers could be eroded nearly completely [99 (3) %] after etching with HCl for 120 s. Erosion was significantly increased after etching with HCl compared with H_3PO_4 ($p < 0.05$; Wilcoxon).

Conclusion

It can be concluded that the pseudointact surface layer of natural enamel lesions in primary teeth can be eroded reliably by etching with 15 % HCl gel for 120 s.

Supported by Deutsche Forschungsgemeinschaft (PA1508/1-1).

Source:

Paris S, Dörfer CE, Meyer-Lueckel H. Surface conditioning of natural enamel carious lesions in deciduous teeth in preparation for resin infiltration. J Dent 2010; 38: 65 – 71

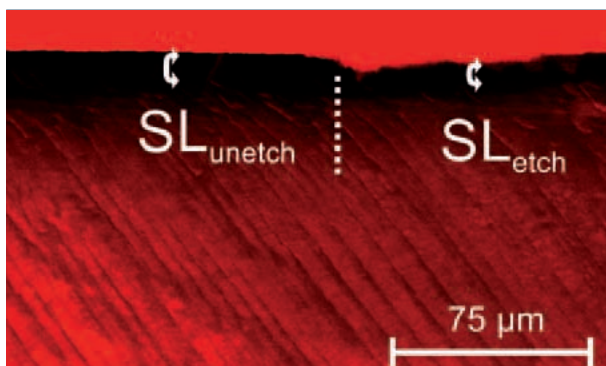


Illustration 1: Slight removal of the surface layer after etching with 37 % H_3PO_4 .



Illustration 2: Considerable removal of the surface layer after etching with 15 % HCl.

Influence of different etching gels on the mineral content of initial enamel lesions in primary teeth

Paris S, Dörfer CE, Meyer-Lückel H.

Department of Operative Dentistry and Periodontology, Christian-Albrechts-Universität, Kiel, Germany

Objectives

To achieve a penetration as deep as possible of low viscous resins (infiltrant) in natural lesions of permanent teeth, the erosion of the surface layer with hydrochloric acid gel (15 %) seems to be suitable. Due to anatomical differences primary teeth may behave different than permanent teeth. The aim of this study was to evaluate the effect of etching with phosphoric or hydrochloric acid on the mineral content of initial enamel lesions in primary teeth.

Methods

Extracted molars of primary teeth with proximal enamel caries were perpendicular cut into two halves. The cut surfaces, parts of the lesions and the sound enamel were covered with nail varnish (control). The halves were either treated with phosphoric acid (37 %) or hydrochloric acid (HCl, 15 %) for 30, 60, 90 or 120 s (n = 8). The specimens were cut and analyzed by micro radiography.

Results

The mineral content of the upper 50 μm of the sound areas and the lesions and the depths of the highest mineral content was determined. ΔZ o,n, (standard deviation) was significantly higher after etching with HCl for 90 s [2.830 (800) vol. % $\times \mu\text{m}$] and 120 s [3.040 (640)] than etching with Phosphoric acid [1.440 (270) resp. 1.550 (530)] (p < 0.05; adjusted paired t-test).

Conclusion

A treatment with HCl for 120 s lead to a complete erosion of the surface layer. This may have a positive influence on the penetration of the infiltrant. This study was supported by Deutsche Forschungsgemeinschaft (PA1 508/1-1).

Source:

Paris S, Dörfer CE, Meyer-Lueckel H. Surface conditioning of natural enamel carious lesions in deciduous teeth in preparation for resin infiltration. J Dent 2010; 38: 65 – 71

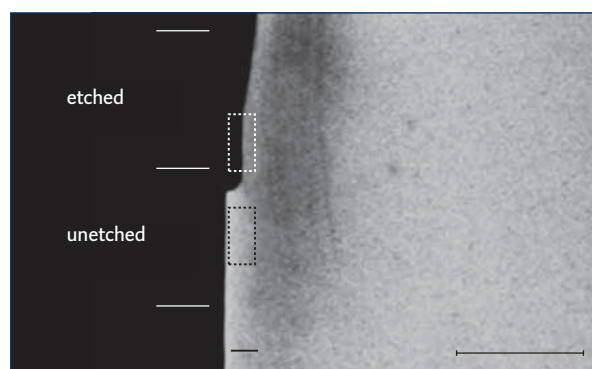


Illustration 1: TMR illustration of the mineral loss prior and after etching.

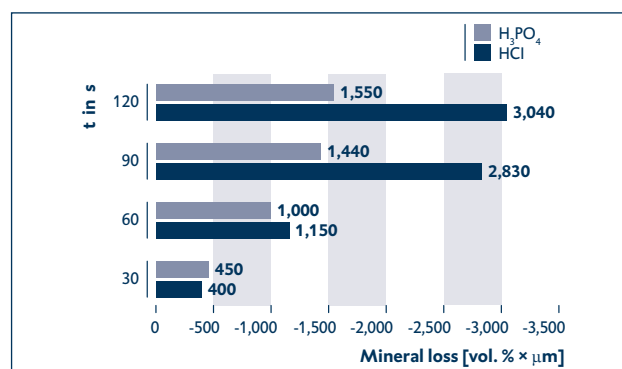


Illustration 2: Mineral loss of deciduous enamel after different etching regimens.

Infiltration of natural caries lesions in primary teeth with experimental infiltrants in vitro

Paris S¹, Chatzidakis AJ², Meyer-Lückel H¹.

¹Department of Operative Dentistry and Periodontology, Charité – Universitätsmedizin Berlin, Berlin, Germany

²Department of Prosthodontics, Gerontostomatology and TMD, Dental School, Charité – Universitätsmedizin Berlin, Berlin, Germany

Objectives

Infiltration of carious enamel with low viscous light cured resins could be a promising treatment to arrest lesions. It is not clear yet whether this new procedure can be used also in primary teeth. The aim of this study was to compare penetration depths of four experimental infiltrants with different composition and penetration coefficients (PK A: 63; B: 185; C: 204; D: 391 cm/s) in natural caries in primary teeth.

Methods

The experimental infiltrants were made from TEGDMA (T), BisGMA (B) and Ethanol (E) in the mixing ratio (T:B:E) A: 75:25:0; B: 60:20:20; C: 100:0:0; D: 80:0:20. 52 exfoliated human primary teeth with natural proximal white spot lesions (ICDAS II: 2) were randomized in 4 groups. To remove the surface layer the lesions were etched for 120 s with 15 % Hydrochloric acid gel. The lesions were dried and the different infiltrants were applied to the surface. After a penetration time of 5 minutes excess was removed and the materials were cured with light. Subsequently the lesions were prepared for the measurement by CLSM with a fluorescent dye.

Results

Infiltrants C and D penetrated significantly deeper [Median (Q₂₅, Q₇₅)] [C: 257 (133, 413) μm; D: 283 (157, 449) μm] than the materials A [184 (98, 318) μm] and B [191 (99, 332) μm] $p < 0.05$; Mann-Whitney).

Conclusion

Non cavitated enamel caries lesions in primary teeth can nearly be completely infiltrated in vitro. Infiltrants with a high PK seem to be better suitable than those with low PK.

The study was supported by Deutsche Forschungsgemeinschaft (DFG) (PA 1508/1-1).

Source:

Paris S, Chatzidakis AJ, Meyer-Lückel H. Einfluss des Penetrationskoeffizienten von Infiltranten auf natürliche Milchzahnkaries in vitro. Autoreferat-Band 22. Jahrestagung der Deutschen Gesellschaft für Zahnerhaltung, ISBN 978-3-86611-406-7, S. 51 (Autoreferat Nr. 27), 2008

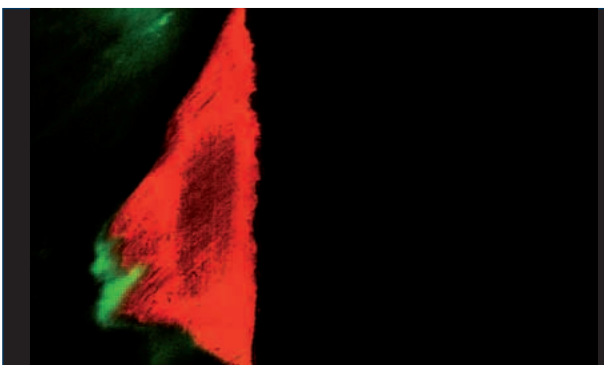


Illustration 1: Infiltrated lesion in a deciduous molar.

Unique treatment of early caries and white spot lesions

Nobrega D, Perry R, Kaminsky E, Finkelman M, Kugel G.

Department of Prosthodontics and Operative Dentistry, School of Dental Medicine, Tufts University, Boston, MA, USA

Objectives

The two currently available methods for treating carious lesions are limited. Prevention (fluoride therapy) is not always effective in advanced stages of caries and invasive methods (drilling and filling) sacrifice healthy tooth structure. Icon (DMG) may arrest caries early without the loss of tooth structure on both proximal and smooth surfaces. The purpose of this study is to determine if Icon increases hardness in artificial caries created in otherwise healthy extracted human teeth.

Methods

Non-cariou molars ($n = 10$) were cut in half (Isomet-1000) and each half randomly assigned to one of two groups: Icon-treated or untreated. Each half was polished (600-grit), a small window created using acid-resistant nail polish (Jennifer Cosmetics Inc., New York, NY), and then placed in demineralizing solution (2.2 mM CaCl_2 , 2.2 mM KH_2PO_4 , 0.05 M acetic acid, pH 4.4) for 120 h. Teeth were removed and placed in water for 24 h. The Icon-treated teeth were etched (Icon-Etch, 2 min), washed (30 s), air-dried (30 s), dried with Icon-Dry (30 s), and air-dried (30 s). Icon-Infiltrant was added (3 min) and light-cured (40 s). A second coat of Icon-Infiltrant was added (1 min) and light-cured (40 s). All teeth were tested using the Vickers Hardness Test (1000 g) and statistically analyzed (Mann-Whitney U Test).

Results

The Mann-Whitney U Test revealed that there was a statistical difference between the two groups ($p < 0.001$).

Conclusion

Artificial caries treated with Icon have a higher VHN than those left untreated. This result may have clinical significance in treating early caries and white spot lesions. Further testing is needed.

Source:

Nobrega D, Perry R, Kaminsky E, Finkelman M, Kugel G. Unique treatment of early caries and white spot lesions. *J Dent Res* 89 (Spec Iss A):2522 (2010)

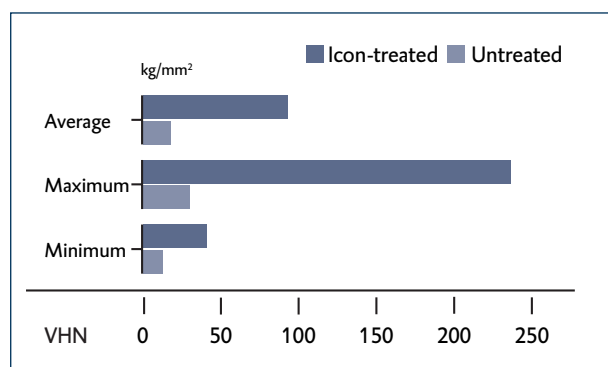


Illustration 1: Micro-Vickers hardness test.

Caries infiltration in teeth varying in ICDAS-II codes in vitro

Meyer-Lückel H, Schuch M, Büchting C, Dörfer C, Paris S.

Department of Operative Dentistry and Periodontology, Christian-Albrechts-Universität, Kiel, Germany

Objectives

Almost complete infiltration of enamel caries with light curing resins (infiltrants) has been shown in vitro for lesions scored as ICDAS-II code 2. The aim of the present study was to evaluate the penetration depths of an infiltrant into natural lesions varying in ICDAS-II scores.

Methods

Eighty-four extracted human teeth showing proximal caries lesions (ICDAS-II code: 2, 3, 4, and 5) were positioned in silicone adjacent to a sound neighboring tooth mimicking the clinical situation. Proximal surfaces were etched with 15 % hydrochloric acid gel for 2 min, dried after application of ethanol, and infiltrated twice (3 min and 1 min). Etching and infiltration steps were performed using a perforated double foil applicator (Icon; DMG, Hamburg, Germany). After removing surplus using floss, the infiltrant was light cured. Ground sections were prepared for analysis of lesion depth (maximum distance from surface to bottom of lesion), percentage of resin infiltrated in relation to demineralized lesion areas (% Inf. demin.) within enamel, percentage of cavitation filled with infiltrant (% Inf. cav.) and percentage of infiltrant in demineralized plus cavitated lesion parts (% Inf. all) using confocal microscopy.

Results

Median maximum lesion depths (25th; 75th percentile) of lesions (maximum lesion depth ≥ 500 μm ; $n = 73$) were 963 (766; 1290) μm .

| ICDAS | Cavitation | n | median (25th ;75th percentile) | | | |
|-------|------------|----|--------------------------------|-----------------|----------------|-------------|
| | | | Lesion depth* | % Inf. demin. # | % Inf. cavit.* | % Inf. all* |
| 2 | no | 16 | 897 (706; 1109) | 73 (39; 97) BC | n/a | 73 (39; 97) |
| 3 | no | 9 | 1251 (729; 1325) | 84 (40; 98) ABC | n/a | 84 (40; 98) |
| | yes | 12 | 954 (742; 1197) | 87 (64; 98) AB | 0 (0; 17) | 73 (56; 87) |
| 4 | no | 7 | 943 (835; 1156) | 34 (22; 75) C | n/a | 34 (22; 75) |
| | yes | 12 | 973 (655; 1524) | 87 (60; 100) AB | 5 (0; 64) | 52 (40; 72) |
| 5 | yes | 17 | 1154 (911; 1424) | 100 (75; 100) A | 0 (0; 30) | 43 (22; 64) |

*No significant differences (Kruskal-Wallis $p > 0.05$), #significant differences (Mann-Whitney; $p < 0.05$) between groups within columns highlighted with superscript letters.

No significant differences between groups within all columns were observed (Kruskal-Wallis test; $p > 0.05$).

Conclusion

Most demineralized parts of caries lesions rated as code 2 and 3 (ICDAS-II) can be infiltrated, whereas cavitated parts could not be filled with the infiltrant.

Supported by the Deutsche Forschungsgemeinschaft (PA 1508/1-2). HML and SP receive a research grant and royalties from DMG, Hamburg, Germany.

Source:

Meyer-Lueckel H, Schuch M, Buechting C, Doerfer C, Paris S. Caries infiltration in teeth varying in ICDAS-II codes in vitro. J Dent Res 89 (Spec Iss B): 2522 (2010)

Effect of caries infiltration technique and fluoride therapy on micro-hardness of enamel caries lesions

Rocha Gomes Torres C, de Souza Ferreira N, Campos Ferreira da Rosa P, Bühler Borges A.

Department of Restorative Dentistry, Universidade Estadual Paulista (UNESP), São José dos Campos, SP, Brazil

Objectives

Enamel white spot subsurface lesions compromise the esthetics and precede cavitation. Therefore they must be halted. The aim of this study was to evaluate the effect of caries infiltration technique and fluoride therapy on microhardness of enamel caries lesions.

Methods

Subsurface caries lesions were produced in 60 bovine specimens with polished enamel surface. The specimens were divided into 4 groups (n=15) according to the treatment used: CON) control – immersion in artificial saliva; DF) daily 0.05% fluoride solution; WF) weekly 2% fluoride gel; IC) resin infiltration (Icon; DMG, Hamburg, Germany). The specimens were kept in artificial saliva and evaluated for Vickers microhardness in four stages: after caries production (C), after 4 weeks (4W) and 8 weeks (8W) of treatment and after a new acid challenge (AC).

Results

The two-way ANOVA showed significant differences for the type of treatment ($p=0.00$) and time of evaluation ($p=0.00$). The means of microhardness and the results of Tukey's test for the kind of treatment were: CON - 45.18 (± 29.17)a; WF - 83.25 (± 51.17)b; DF - 107.75 (± 67.38)c; IC=160.83 (± 91.11)d. The groups followed by the same letters did not present significant differences.

The means of microhardness for all the groups and moments of evaluation were: DF-C (16,33 \pm 4.45)a; CON-C (18.84 \pm 9.93)a; WF-C (21.05 \pm 10.59)a; IC-C (22.48 \pm 8.04)a; CON-4W (53.53 \pm 32.48)abc; CON-8W (67.62 \pm 28.58)bc; WF-4W(92.31 \pm 30.14)cd; WF-AC (95.10 \pm 37.13)cd; WF-8W (124.52 \pm 49.27)de; DF-4W (129.72 \pm 57.49)de; DF-AC (138.63 \pm 38.94)e; DF-8W (146.31 \pm 46.98)e; IC-AC (160.99 \pm 46.13)e; IC-8W (225.76 \pm 29.00)f; IC-4W (234.11 \pm 34.26)f. The groups followed by the same letters did not present significant differences.

Conclusion

It was concluded that the microhardness of carious lesions increased with the Icon application and the ability to withstand a new acid challenge was similar for the daily fluoridation group (DF) and resin infiltration group (IC).

Source:

Rocha Gomes Torres C, de Souza Ferreira N, Campos Ferreira da Rosa P, Bühler Borges A. Effect of caries infiltration technique and fluoride therapy on microhardness of enamel caries lesions. 2010, Data on file. DMG, Hamburg, Germany

Infiltration of natural caries lesions with monomer under simulated conditions of the oral cavity

Schneider H, Albert M, Busch M, Häfer M, Jentsch H.

Department of Conservative Dentistry and Periodontology, University of Leipzig, Leipzig, Germany

Objectives

The infiltration of natural enamel caries lesions with resin ("infiltrant") was to be assessed in vitro after setting of relative humidity (rH) to values according to an in-vivo treatment with or without rubber dam application. Hypothesis: With lower rH the penetration of the infiltrant is enhanced.

Methods

N = 6 extracted human molars with enamel caries lesions, 2 cuts of each across the centre of lesions perpendicular to their surfaces (corresponding halves), 2 groups of lesion halves (G 1: rH 37–45 %, corr. to rubber dam application, control; G 2: rH 78–90 %, corr. to no rubber dam application; 27–30 °C each), covering cutted areas with nail varnish, infiltration with resin accord. to instruction (moist chamber, infiltrant, exp. charge, DMG, Hamburg, Germany), embedding of corresponding halves in Stycast, removal of nail varnish, preparation of specimens for scanning electron microscopy (SEM, 3 layers of each). Assessment criteria: percentage of resin penetration (area of penetrated resin:area of lesion, %), penetration depth, homogeneity of resin penetration (grades 1/2: homogeneous/inhomog.), residual surface layer (y/n). Statistics: Wilcoxon test, $\chi^2 = 0.0166$, tendency: $p < 0.08$.

Results

The hypothesis is not valid. The percentages of resin penetration between G 1 ($26.9 \pm 15.2\%$) and G 2 ($24.7 \pm 16.1\%$) were non-significantly different ($p = 0.313$), just as the penetration depths (G 1: $113.9 \pm 65.6 \mu\text{m}$, G 2: $90.6 \pm 61.6 \mu\text{m}$, $p = 0.313$), the penetration was more inhomogeneous in G 2 (4.0 ± 2.5) than in G 1 (2.8 ± 1.7 , $p = 0.063$, sum of grades), residual surface layers were observed generally.

Conclusions

A lower rH (corr. to rubber dam application) seems not to enhance the resin penetration but seems to enhance its homogeneity. There is a potential for resin penetration and the removal of the residual surface layer. Investigations are in progress.

Source:

Schneider H. Infiltration of natural caries lesions with monomer under simulated conditions of the oral cavity. 2008, Data on file. DMG, Hamburg, Germany




Illustration 1+2 : Enamel lesion after infiltration with monomer (1, REM), Monomer penetration in the lesion (2). Rest of surface layer (OS), Penetrated monomer (M), Non infiltrated parts of the lesion (L), Sound enamel (S).

Resin infiltrated artificial caries lesions examined by polarized light microscopy and micro-hardness tests

Palamara JEA, Tyas M, Burrow MF.

Melbourne Dental School, The University of Melbourne, Melbourne, VIC, Australia

Objectives

The aim of the study was to show the extent of penetration and change in hardness of porous artificial enamel lesions infiltrated with a light-cured resin using cross polarized light microscopy and micro Vickers hardness respectively.

Methods

Extracted human teeth were prepared to obtain subsurface lesions (~250 μm deep) after 12 days in de-mineralizing solution. White spots lesion were formed on buccal, lingual and proximal surfaces. The buffer (a modified version of White DJ, 1987 Caries Res 21:228-242.) consisted of 80 mL/L polyacrylate solution, 500 mg/L hydroxyapatite, and 0.1 M lactic acid with the pH adjusted to 4.8 using NaOH. Two demineralized areas of each tooth were penetrated with the infiltrant twice according to the instructions for use while the other two acted as controls. Crossed polarized light microscopy with the imbibition of different refractive index (RI) media (aqueous solution RI = 1.33 to 1.62) was used to investigate the depth of penetration of the infiltrant, and micro-Vickers hardness test was used to investigate the change in hardness of the inner and outer half of the lesions.

The statistical evaluation was done by student's t-test ($p < 0.05$) on demineralized and demineralized-infiltrated enamel. Artificial lesions showed a significantly higher hardness after infiltration of both the inner and out half (both $p < 0.0001$) (Illustration 1).

Results

Resin penetration was clearly observed macroscopically and in the "body" of the artificial lesion using imbibition techniques with crossed polarized light microscopy (Illustration 2).

Conclusion

Infiltration of resin penetrates and seals voids in the "body" of the artificial lesions and significantly improves its hardness.

Source:

Palamara JEA, Tyas M, Burrow MF. Resin infiltrated artificial caries lesions examined by polarized light microscopy and micro-hardness tests. 2010, DMG, Hamburg, Germany

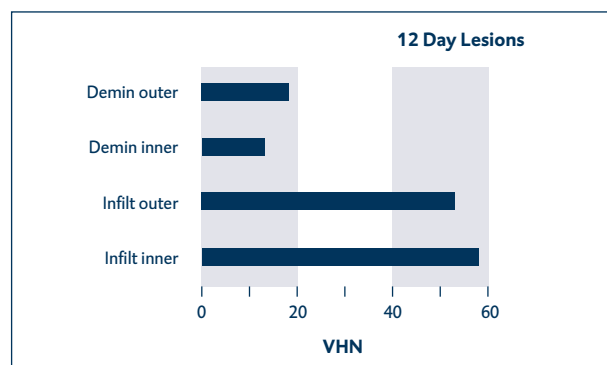


Illustration 1: Micro-Vickers hardness tests.




Illustration 2: Crossed polarized light micrograph of non infiltrated artificial lesion. (Field of view = 570 μm). Solution RI = 1.62.

In vitro color stability of infiltrated caries lesions

Lübbers D, Spieler-Husfeld K, Staude C.

Scientific Affairs, DMG Dental-Material Gesellschaft mbH, Hamburg, Germany

Objectives

Caries infiltration is a promising novel approach for the treatment of incipient lesions of smooth labial surfaces. Color stability of the infiltrated areas is the key factor for the long term clinical success. This study aimed to determine the color stability of infiltrated carious lesions subject to staining during the exposure to light irradiation (sun test).

Methods

24 artificial incipient lesions were created out of bovine incisors following a demineralization protocol. Specimens were subdivided in two groups (n = 12): Group A served as a control and was stored in aqua dest. for 14 days. Group B underwent a sun test (exposure to Sunbeam radiation for 15 minutes, for 2' in tap water and the remaining time of 23 h 43' in aqua dest. for 14 consecutive days). To differentiate between extrinsic and intrinsic stain, specimens were polished after the last discoloration cycle using an electrical toothbrush (Oral-B, Vitality, Procter&Gamble, Schwalbach, Germany) and toothpaste (elmex, GABA, Loerrach, Germany). CIE L*a*b* values, were taken at four intervals: at baseline, 24 h after infiltration, after discoloration cycles and after final polishing. A small-area colorimeter was used.

Results

ΔL , Δa , Δb and ΔE values were calculated to determine the extent of color change. In this test no difference between the two groups could be detected. This corresponds to a ΔE value < 2 .

Conclusion

Within the limitations of this test infiltrated artificial lesions are not sensitive to discoloration by sun light.

Source:

Luebbers D, Spieler-Husfeld K, Staude C. In vitro color stability of infiltrated carious lesions. 2009, Data on file. DMG, Hamburg, Germany

Effect of caries infiltration technique and fluoride therapy on the color masking of white spot lesions

Rocha Gomes Torres C, Marcondes Sarmiento Torres L, Silva Gomes I, Simões de Oliveira R, Bühler Borges A.
Department of Restorative Dentistry, Universidade Estadual Paulista (UNESP), São José dos Campos, SP, Brazil

Objectives

A carious lesion is initiated through the subsurface demineralization of enamel, and presents clinically as a white spot, interfering on the esthetics. This lesion should not receive restorative treatment because it is capable of remineralization. The aim of this study was to evaluate the performance of different treatments on masking white spot lesions by assessing the color change.

Methods

Artificial white spot lesions were produced in bovine enamel of 60 cylindrical samples. The samples were randomly divided into four groups: CON) control - immersion in artificial saliva, DF) daily application of fluoride solution 0.05 %, WF) weekly application of fluoride gel 2 % IC) infiltration of resin (Icon; DMG, Hamburg, Germany). The assessment of color was performed by a spectrophotometer in five distinct stages: baseline, after the production of artificial caries (C), after 4 weeks (4W), after 8 weeks (8W), and after new acid challenge (AC). The ΔL values were calculated for each moment in relation to the baseline color.

Results

The two-way ANOVA showed significant difference for the kind of treatment and time of evaluation ($p < 0.05$). The means of ΔL and the results of Tukey's test for the factor group were: IC - 0.59a; DF - 1.80b; CON - 2.44b; WF - 2.63b. The groups followed by the same letters did not present significant differences. The means of ΔL for all the groups and moments of evaluation were: IC-8W (-2,30)a; IC-4W (-1.76)ab; IC-AC (-0.50)abc; DF-8W (0.47)abc; CON-8W (0.95)abc; DF-4W (1.44)abc; WF-8W (1.77)abc; IC-AC (2.18)bc; DF-AC (2.26)bc, WF-AC (2.32)bc; WF-AC (2.64)c; CON -AC (2.68)c; CON-4W (2,79)c; DF-AC (3.04)c; CON-AC (3.33)c; WF-4W (3,79)c. The groups followed by the same letters did not present significant differences.

Conclusion

Icon was the most effective treatment for masking white spot lesions, followed by 0.05 % fluoride solution. Besides, after a new acid challenge, the group infiltrated with Icon was more resistant to new formation of white spot.

Source:

Rocha Gomes Torres C, Marcondes Sarmiento Torres L, Silva Gomes I, Simões de Oliveira R, Bühler Borges A. Effect of caries infiltration technique and fluoride therapy on the color masking of white spot lesions. 2010, Data on file. DMG, Hamburg, Germany

Visual assimilation of artificial enamel caries lesions by infiltration in vitro

Paris S, Keltsch J, Dörfer CE, Meyer-Lückel H.

Department of Operative Dentistry and Periodontology, Christian-Albrechts-Universität, Kiel, Germany

Objectives

Infiltration of caries lesions with light-curing resins is efficacious to inhibit further lesion progression. As a positive 'side effect' the whitish appearance of caries lesions is altered by the penetrating resin due to reduction of light scattering. The aim of this in vitro study was to assess the effect of resin infiltration on the visual appearance of artificial caries lesions.

Methods

In each of 20 bovine enamel specimens two artificial lesions were created (pH 4.95, 50 d), leaving two sound windows of enamel. After etching (37 % H₃PO₄, 3 s) in each specimen one lesion and one sound window were infiltrated (Icon; DMG, Hamburg, Germany). The other (untreated) lesion and sound window served as negative and positive controls, respectively. Half of the four areas of each specimen was polished (removal ~15 µm). Specimens were remineralized (pH 7.0) for 25 days. During that period specimens were additionally stored in a coffee/red wine mixture (1:1) for 10 min daily and brushed with fluoride toothpaste (1400 ppm) 12 h later. After infiltration as well as after the remineralization period standardized photographs were taken and L*a*b*-color values were measured (Photoshop CS4). Color differences compared to positive controls (ΔE) were calculated for each area.

Results

After infiltration, ΔE-values [median (Q25/Q75)] of infiltrated lesion [7 (6/10)] and infiltrated sound areas [4 (3/6)] were significantly lower compared with those of negative controls [20 (17/22)] (p < 0.001; Wilcoxon). After remineralization, infiltrated polished lesion areas [6 (5/8)] showed significantly lower ΔE-values compared with (unpolished) negative controls [11 (6/15)] (p < 0.05).

Conclusion

Compared to remineralization alone, infiltration in combination with remineralization resulted in better assimilation of the appearance of artificial enamel lesions to adjacent sound enamel.

Supported by the Deutsche Forschungsgemeinschaft (PA1508/1-2).

Source:

Paris S, Keltsch J, Dörfer CE, Meyer-Lückel H. Visual assimilation of artificial enamel caries lesions by infiltration in vitro. Caries Res 44: 171–248, Abs. 41, (2010)

In vitro resistance of resin infiltrated initial caries lesions (white spots) against tooth brush abrasion

Lohbauer U, Ebert J, Schubert EW, Petschelt A.

Dental Clinic 1 – Conservative Dentistry and Periodontology, University of Erlangen-Nuremberg, Erlangen, Germany

Objectives

To stop caries already in the initial stage a special infiltration method for the so called “white spots“ has been developed. Porous enamel lesions are infiltrated with a light-cured resin. White spots can be found in proximal as well as in vestibular areas. Especially in vestibular areas the infiltrated areas are subject to abrasion. The resistance to tooth brushing is therefore very important for the longevity of the treatment.

Methods

Fresh extracted bovine teeth were prepared to get a smooth parallel area, which was subdivided in 4 areas (not treated–not brushed [1], not treated-brushed [2], demineralized-infiltrated-brushed [3], demineralised-brushed [4]). The areas 1 and 2 were protected against demineralization. The specimens (n = 8) were demineralized in a special demineralization solution (Buskes, Christoffersen et al. 1985) at pH-value of 4.95 for 30 days until lesions of about 200 μm were created. 2 demineralized areas were penetrated with the infiltrant twice according to the instructions for use. The abrasion tests were performed with a computer controlled tooth brush machine (Willitec, Munich, Germany). The abrasive medium was a commercial available tooth paste Elmex (GABA, Loerrach, Germany), which was modified with an emulgator (Tragant). Standardized tooth brushes (Oral-B 40, medium hardness) with a brushing area of 184 mm^2 and a pressure of 1,9 N (ISO 14569-1) were used. An 8-shaped brushing procedure and a maximum of 10000 brushing cycles were chosen to avoid local build up of frames. The abraded enamel surfaces were observed with Confocal Laser Scanning Microscope (TCS SL, Leica, Bensheim, Germany) at a magnification of 200. The abraded surfaces 2, 3 and 4 were referenced to surface 1. The statistics were evaluated by Variance Analysis ANOVA (mod. LSD-Test, $p < 0.05$).

Results

Infiltrated lesions showed a slightly higher abrasion than sound enamel.

Conclusion

Infiltration reinforces artificial lesions with respect to abrasion resistance.

Source:

Lohbauer U, Ebert J, Schubert EW, Petschelt A. In-vitro-Resistenz von kunststoff-infiltrierter Initialkaries (White Spots) gegenüber Zahnbürstabrasion. 2009, Data on file. DMG, Hamburg, Germany

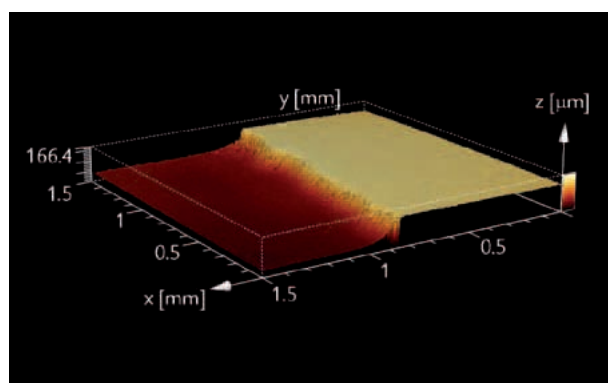


Illustration 1: 3-D Illustration of abrasion traces (Magnification: 200x).

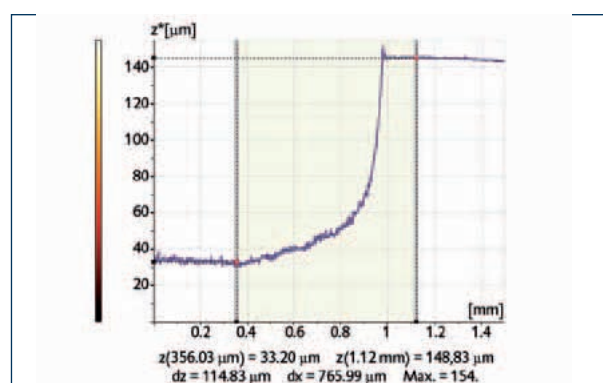


Illustration 2: Abrasion profile (dz-Value).

Surface roughness determination of a caries infiltrant resin

Burgess JO, Cakir D.

Department of Prosthodontics, School of Dentistry, University of Alabama, Birmingham, AL, USA

Objectives

Surface roughness can lead to excessive plaque accumulation, increased surface staining, and poor or less than optimal esthetics of the restored teeth. This in vitro study was designed to 1) determine the surface roughness of “caries infiltrant resin” after the application on enamel surface and to 2) compare surface roughness values of finished and unfinished surfaces and natural lesion to the values of sound enamel.

Methods

Freshly extracted molars were collected and polished using polishing caps and pumice to remove stains and tiny deposits of calculus. The teeth were then gently air-dried and visually examined using a 30x magnifying lens and overhead lamp for early white spot lesions in the plaque retentive areas. Only teeth with no cracks, restorations, forceps lesions or other developmental lesions were selected and divided into 4 groups (n = 10), (A) Infiltrant with finished surface, (B) Infiltrant without surface treatment, (C) Natural enamel, (D) Carious enamel. The teeth specimens were then sectioned at the Cemento-enamel junctions, only the crowns were retained for purposes of this study. The crowns were further sectioned in to rectangular blocks with smooth surfaces and those blocks were then embedded in a putty material, in a way that ensured that the convex smooth tooth surfaces were as parallel to the scanning stage as possible. Through the entire procedure, the teeth hydration was maintained. The lesions were treated with Icon kit for caries infiltration (DMG, Hamburg, Germany) according to manufacturer’s instructions. The samples were scanned using a 3-D non-contact surface profilometer (Proscan2000, Scantron, UK). Acceptable light intensity and depth were attained by adjusting the Z axis of the sensor. ISO standards were followed for cut-off and filter application on the scanned image. A surface filter of 133 was applied.

Results

Cut-offs of 0.4 on each side of the image were applied to give the final image analysis. The Ra mean X and Y surface readings were recorded and analyzed using ANOVA followed by Dunnett’s post-hoc test ($p = 0.05$). The statistical analysis showed no significant differences in surface roughness between all 4 groups, for X and Y analysis ($p > 0.05$).

Conclusion

Caries Infiltration does not lead to an increased surface roughness of infiltrated lesions compared to sound enamel.

Source:

Burgess JO, Cakir D. Surface Roughness Determination of a Caries Infiltrant Resin. 2009, Data on file. DMG, Hamburg, Germany

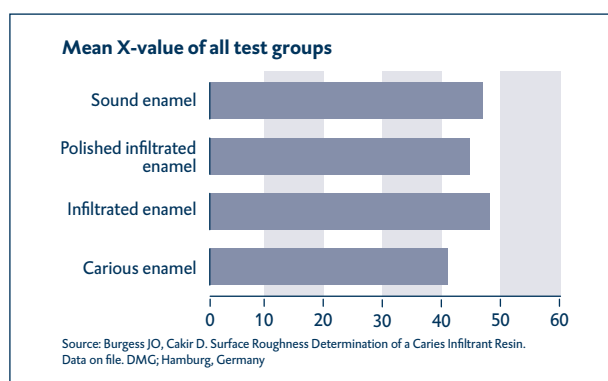


Illustration 1: Mean X values show no significant differences between all 4 groups.

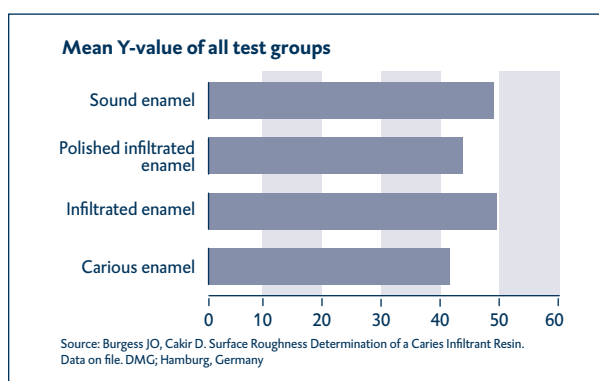


Illustration 2: Mean Y values show no significant differences between the all 4 groups.

Preventing capability of resin-infiltration-technique on occlusal fissures

Horuztepe SA, Firat E, Gurgan S, Onen A, Abaci S.

Department of Restorative Dentistry, Hacettepe University, Ankara, Turkey

Objectives

To compare the effect of resin infiltration technique with topical fluoride and conventional fissure sealant applications on the sub-surface chemical composition changes of demineralized occlusal fissures under simulated oral conditions.

Methods

Sixty-four extracted intact human third molar were used in this study. After adequate storage and surface debridement, the occlusal surfaces were subjected to demineralization solution to obtain standard lesions on occlusal fissures. The teeth were then randomly divided into four groups according to preventive applications (n=16). G1: No preventive treatment was applied and the demineralized specimens were used as control; G2: Topical fluoride application (APF Gel/ DEEPAK); G3: Fissure sealant application (Clinpro™Sealant/3M ESPE); G4: Resin infiltration technique (Icon; DMG, Hamburg, Germany). Eight specimens from each group were kept to evaluate the immediate chemical composition changes and the remaining 8 teeth from each group were subjected to pH-cycling for 15 days to simulate the oral conditions. Subsequently, the specimens were fractured along the pre-formed slits by immersion in liquid nitrogen to provide a clear sagittal view and the sub-surface Calcium (Ca), Phosphorus (P), Potassium (K), Sodium (Na), Magnesium (Mg), Fluorine (F) and Oxygen (O) levels of each specimen were measured using an energy dispersive spectrometer (Bruker Axs XFlash 3001 SDD-EDS). SEM investigations were performed for the qualitative evaluation of surface topography. The data were subjected to statistical analysis for the changes in sub-surface mineral levels ($p = 0.05$).

Results

All three preventive applications were found to be effective after 15 days pH-cycling ($p < 0.05$). The change in chemical compositions among the preventive applications were not statistically significant ($p > 0.05$). SEM examinations supported the chemical analysis results.

Conclusion

The preventing capability of resin-infiltration-technique on occlusal fissures was comparable with conventional topical fluorid and fissure sealant applications.

Source:

Horuztepe AS, Firat E, Gurgan S, Onen A, Abaci S. Preventing Capability of Resin-infiltration-technique on Occlusal Fissures. J Dent Res 89 (Spec Iss B): 2520 (2010)




Illustration 1: SEM picture of the infiltrated lesion.




Illustration 2: SEM picture of the infiltrated lesion after pH-cycling.

Influences on bond strength of orthodontic brackets

Phark JH¹, Choo KM¹, Duarte S¹, Sadan A².

¹Department of Comprehensive Care, Dental School, Case Western Reserve University, Cleveland, OH, USA

²Division of Restorative Sciences, School of Dentistry, University of Southern California, Los Angeles, CA, USA

Objectives

The aim of this study was to examine the effect of enamel treatment, demineralization, resin infiltration, and aging on bond strengths of orthodontic brackets to human enamel.

Methods

Sixty extracted mandibular molars were selected, split in two halves, and randomly assigned into two groups: (1) orthodontic brackets bonded with self-etching primer (SE; Transbond Plus Self-Etching Primer), (2) orthodontic brackets bonded after 35 % phosphoric acid followed by the application of a TEGMA/Bis-GMA primer (TE; Transbond XT Etching Gel+ Transbond XT Primer). Each tooth was then allocated into three experimental settings as: intact, non-demineralized (ND), demineralized (D), demineralized+resin infiltrated with Icon (DRI). For groups D and DRI the specimens were immersed in a demineralizing solution (pH = 4.95) for 8 weeks. The specimens were tested for bond strengths after 24 hours and after artificial aging (20,000 thermal cycles). Shear bond strengths (SBS) was performed using a universal testing machine. Statistical analysis was calculated using ANOVA/Tukey's B post-hoc test at = 0.05.

Results

(SBS±SD in MPa)

| | Non-aged | | Aged | |
|--------|------------|----|------------|----|
| TE-ND | 152.5±45.8 | ab | 245.7±52.5 | c |
| TE-D | 202.2±57.1 | bc | 259.2±44.0 | c |
| TE-DRI | 202.9±37.0 | bc | 187.9±38.3 | b |
| SE-ND | 102.9±24.5 | a | 139.5±67.5 | ab |
| SE-D | 167.1±53.1 | ab | 227.1±55.6 | c |
| SE-DRI | 156.5±65.6 | ab | 124.3±48.1 | a |

Different letters indicate significant statistical differences.

Conclusion

SBS of orthodontic brackets are influenced by etching technique, demineralization, and artificial aging. Resin infiltration of demineralized enamel does not affect the bond strength of orthodontic brackets.

Source:

Phark JH, Choo KM, Duarte S, Sadan A. Influences on Bond Strength of Orthodontic Brackets. J Dent Res 89 (Spec Iss A): 1320 (2010)

In vivo studies

In vivo studies “caries infiltration”

In vitro studies have proven the concept of caries infiltration in terms of physical properties, infiltration of lesion and lesion progression. To take this approach one step further to the daily clinical use, clinical efficacy had to be proven. In a first phase several clinical studies were initiated to prove the clinical efficacy for both applications.

In randomized controlled clinical trials (RCTs) the efficacy of the caries infiltration is tested. The studies are conducted in split-mouth design. Lesion progression is determined based on bitewing radiographs which are evaluated by pairwise-reading and subtraction radiography. The follow-up period for the proximal infiltration is 12 –18 months. Efficacy in hampering lesion progression is tested in different substrates, deciduous and permanent teeth, and in populations with different levels of caries experience, caries risk and caries progression rates.

Longterm color stability is investigated in studies concerning the efficacy of the vestibular infiltration by varying color measuring techniques. The observation period is between 1–12 months. Furthermore studies regarding dentist and patient acceptability and satisfaction are conducted.

Caries diagnosis and caries prevention procedures in dental practices in Germany

Lawrenz MC, Cachovan G, Effenberger S, Schiffner U.

Department of Restorative and Preventive Dentistry, University of Hamburg, Hamburg, Germany

Objectives

The reduction in cavities in children and young people witnessed during recent years can also be attributed to the implementation of preventative measures by dental practices. This study was intended to obtain an overview of the preventative measures carried out here.

Methods

For this purpose a survey was conducted of practicing dentists in Germany in the form of a questionnaire, which evaluated a broad spectrum of possible measures for a range of patient age groups. The questionnaire was sent to a random sample of 5 % of the dentists in Germany. The evaluation took place descriptively and analytically with reference to selected practitioner-related parameters such as gender, years in the profession and specialist personnel employed (SPSS, Chi²-Test).

Results

1428 questionnaires were evaluated (36.8 % female and 63 % male responders, rate of return 35.7 %). 99.2 % of the survey participants offer preventative services, 78.6 % have personnel employed for this. A high degree of agreement was expressed in relation to the requirement for motivation measures for oral hygiene and nutrition. Differentiation is made between the application of fluoridation measures in the practices: For children under 6 years this is not carried out by 20.2 % of the responders. In contrast fluoridation is carried out on an extremely wide basis (97.3 %) in patients aged 6 – 17 years. Fissure sealing is implemented by 93.6 % of survey participants, with the majority (57.4 %) restricted to molars in 6 – 17 year olds. Here, it is significantly more common for dentists with greater professional experience to carry out preventative measures exclusively within the framework of the statutory health insurance. In the case of adults, preventative measures are carried out significantly more commonly in conjunction with parodontal treatments than with filling therapies. It was possible to confirm the survey results through a follow-up non-responder analysis conducted by fax with 8 questions.

Conclusion

The study showed that preventative measures are an integral component of German dental practices and that these are largely carried out by skilled personnel. In the case of children the measures are predominantly concentrated on patients between the ages of 6 and 17 years. The prevention of cavities during these years is thereby strongly orientated towards the framework conditions of the statutory health insurance.

Supported by DMG, Hamburg, Germany.

Source:

Lawrenz MC, Cachovan G, Effenberger S, Schiffner U. Caries diagnosis and caries prevention procedures in dental practices in Germany. 2010, Data on file. DMG, Hamburg, Germany.

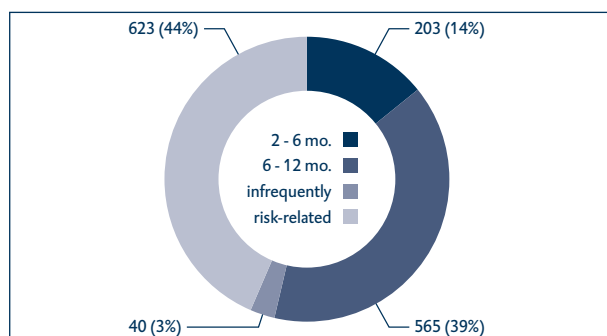


Illustration 1: Frequency and indications for topical fluoride application.

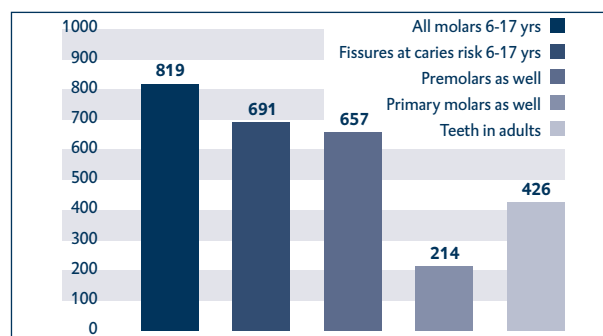


Illustration 2: Frequency and localization for fissure sealings.

Progression of infiltrated artificial enamel caries lesions in situ

Paris S^{1,2}, Meyer-Lückel H^{1,2}.

¹Department of Operative Dentistry and Periodontology, Charité – Universitätsmedizin Berlin, Berlin, Germany

²Department of Operative Dentistry and Periodontology, Christian-Albrechts-Universität, Kiel, Germany

Objectives

The aim of the present study was to assess the efficacy of resin infiltration to prevent further demineralization in situ.

Methods

Two artificial enamel caries lesions were created in each of 40 bovine enamel specimens (demineralization solution, pH 4.95, 14 d). In the test group one of the lesions was etched for 5 s and subsequently infiltrated with a pre-product infiltrant (DMG) twice for 60 s. In a positive control group one lesion was superficially sealed with a fissure sealant (Clinpro Sealant, 3M Espe, Seefeld, Germany). The second lesion in each specimen served as untreated control. Specimens were embedded in intraoral appliances that were worn by six volunteers for 100 days. Plaque accumulation was promoted by protecting the specimen's surface with a mesh and storing the appliances in 10 % sucrose solution (2×30 min/day). Specimens were analyzed using Transversal-Microradiography (TMR).

Results

Baseline lesion depths [mean (SD); LD = 98 (19) μm] and mineral losses [$\Delta Z = 2465$ (472) vol. % $\times\mu\text{m}$] did not differ significantly between various groups ($p > 0.05$; paired t-test). After in situ phase untreated controls had progressed significantly [LD = 206 (72) μm , $\Delta Z = 6694$ (2322) vol. % $\times\mu\text{m}$; $p < 0.05$]. In contrast, infiltrated [LD = 99 (20) μm , $\Delta Z = 2872$ (527) vol. % $\times\mu\text{m}$] and sealed [LD = 97 (20) μm , $\Delta Z = 2441$ (667) vol. % $\times\mu\text{m}$] lesions showed no significant progression ($p > 0.05$).

Conclusion

It can be concluded that resin infiltration is efficacious in preventing further demineralization of enamel caries lesions under cariogenic conditions in situ.

Source:

Paris S, Meyer-Lueckel H. Caries inhibition by infiltrants in situ. Caries Res 43: 228, (Abst. No.136), (2009)

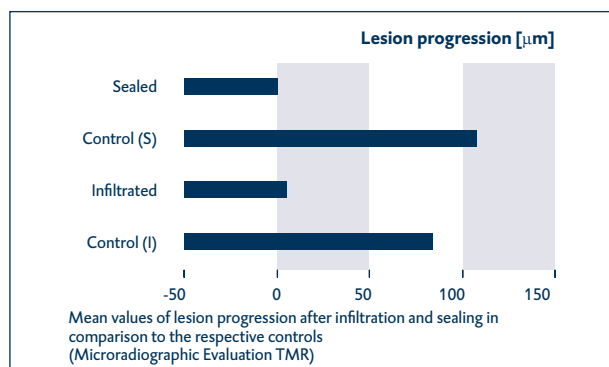


Illustration 1: TMR results of lesion progression before and after etching.

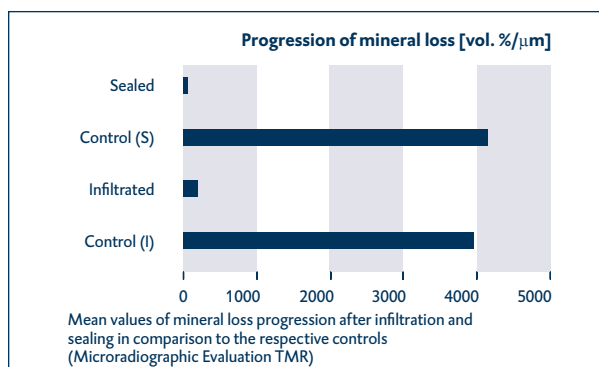


Illustration 2: Progression of mineral loss after different pre-treatments.

Effects of application time on infiltrant caries penetration *ex vivo*

Mendes Soviero V¹, Paris S², Séllos M¹, Meyer-Lückel H².

¹Department of Pediatric and Community Dentistry, Dental School, Universidade do Estado do Rio de Janeiro (UERJ), Rio de Janeiro, RJ, Brazil

²Department of Operative Dentistry and Periodontology, Christian-Albrechts-Universität, Kiel, Germany

Objectives

The aim of this pilot study was to estimate the sample size for an *ex-vivo* study evaluating the influence of application time on penetration depth of a low viscosity resin (infiltrant) into proximal caries lesions in primary molars.

Methods

Ethical approval was obtained and parents gave informed consent. Fifteen primary molars with proximal caries lesion diagnosed radiographically with radiolucencies restricted to the enamel (E1, E2) or in the outer third of dentine (D1) and expected to exfoliate within the next 6 months were selected. Proximal lesions were treated with an infiltrant (Icon; DMG) using three application times (60 s, 180 s, 300 s) *in vivo*. After treatment, teeth were extracted and thin sections were prepared. Lesion depth was analyzed using polarization light microscopy. Subsequently, specimens were etched with 5 % HCl (30 s) and penetration depth was analyzed using backscattered scanning electron microscopy.

Results

Sample size calculation based on mean percentage penetration depths revealed that 33, 14, and 94 specimens are needed to obtain significant differences between 60 s/180 s, 60 s/300 s, and 180 s/300 s application time, respectively ($\alpha = 0.05$; $1 - \beta = 0.8$; chi-square test).

| Time (s) | N | median (25th; 75th percentile) [μm] | | |
|----------|---|--|-------------------|---------------------|
| | | Lesion depth | Penetration depth | % Penetration depth |
| 60 | 4 | 487 (182; 644) | 283 (128; 511) | 74 (49; 93) |
| 180 | 6 | 642 (472; 757) | 481 (341; 580) | 82 (71; 85) |
| 300 | 4 | 616 (525; 874) | 520 (376; 795) | 91 (66; 93) |

No significant differences between groups within all columns were observed (Kruskal-Wallis test; $p > 0.05$).

Conclusion

Even after a relatively short application time of an infiltrant (1 min), shallow lesions in primary molars seem to be thoroughly infiltrated. Sample size calculation revealed that more than 30 teeth are needed, to show significant different percentage penetration depths between clinically relevant application times.

Supported by the Deutsche Forschungsgemeinschaft (PA 1508/1-2). HML and SP receive a research grant and royalties, VS receives a research grant from DMG, Hamburg.

Source:

Soviero V, Paris S, Séllos M, Meyer-Lueckel H. Effects of Application Time on Infiltrant Caries Penetration *ex vivo*. J Dent Res 89 (Spec Iss A): 2521 (2010)

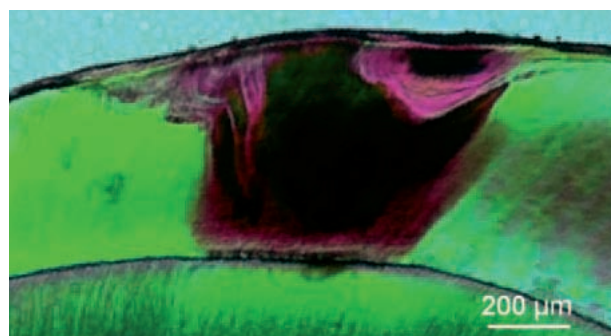


Illustration 1: Polarisation microscopic image of a fully in-situ infiltrated lesion.




Illustration 2: SEM picture of the lesion.

Acceptability of micro-invasive treatment for non-cavitated proximal lesions in children

Mendes Soviero V¹, Soares de Oliveira B¹, Aparecida de Lima Ferreira M¹, Garcia dos Santos M².

¹Department of Pediatric and Community Dentistry, Dental School, Universidade do Estado do Rio de Janeiro (UERJ), Rio de Janeiro, RJ, Brazil

²Fundação para o Desenvolvimento Científico e Tecnológico da Odontologia (FUNDECTO), Universidade de São Paulo (USP), São Paulo, SP, Brazil

Objectives

The aim is to evaluate the acceptability of micro-invasive treatment for non-cavitated proximal lesions through the infiltration technique in children. In contrast to sealing, where the resin layer is on the surface, caries infiltration aims to create a resinous barrier inside the lesion, occluding porosities used as pathways by acids.

Methods

Attempts to infiltrate lesions with adhesives/sealants resulted in superficial penetration. A low viscosity resin with high penetration coefficient, Icon (DMG, Hamburg, Germany), was able to infiltrate natural lesions nearly completely. Twenty-four lesions, in 20 children, 7–10 years-old, were treated with Icon. To assess acceptability, a pain scale, ranging from 0 (no pain) to 5 (worst pain), was used after rubber-dam placement and after the placement of the wedge to separate teeth.

Results

At both, scores were mainly concentrated between 0 and 2, although 2 children pointed 5 after wedge. Caries infiltration is conservative and practically unpainful being, therefore, feasible for children.

Conclusion

Caries infiltration is conservative and practically unpainful being, therefore, feasible for children.

Source:

Mendes Soviero V, Soares de Oliveira B, Aparecida de Lima Ferreira ME, Garcia dos Santos M. Aceitabilidade do tratamento micro-invasivo para lesões proximais não cavitadas em crianças. FC 76, ID 6518, FDI, Salvador de Bahia, Brazil (2010)

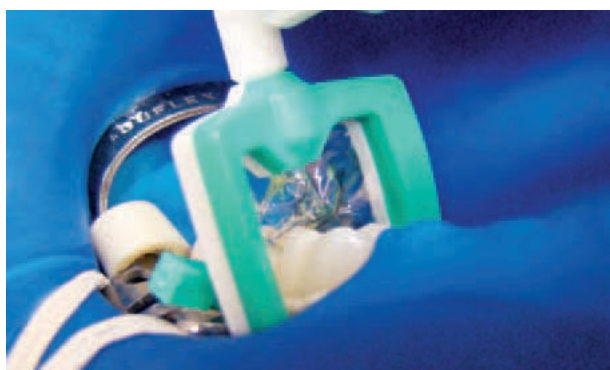

Illustration 1: Temporary tooth separation using the wedge technique.

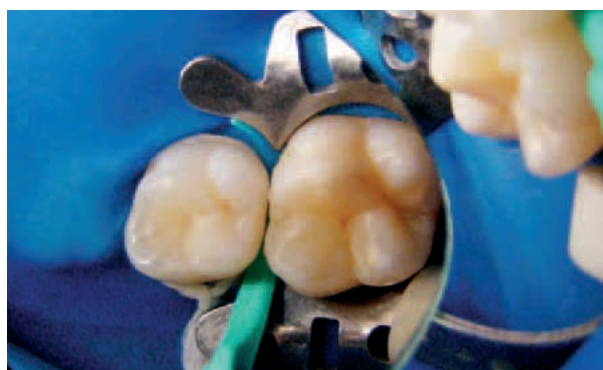


Illustration 2: Accessibility of the interproximal regions using special applicators.

Resin infiltration of caries lesions: an efficacy randomized trial – 18 months follow-up

Paris S^{1,2}, Meyer-Lückel H^{1,2}.

¹Department of Operative Dentistry and Periodontology, Charité – Universitätsmedizin Berlin, Berlin, Germany

²Department of Operative Dentistry and Periodontology, Christian-Albrechts-Universität, Kiel, Germany

Objectives

The aim of this study was to assess the efficacy of resin infiltration of proximal carious lesions with a low-viscous resin (infiltrant).

Methods

In 22 patients (informed consent, IRB approval) 29 pairs of proximal lesions with radiological extension inner half of enamel or outer third of dentin were selected. Lesions were randomly allocated to one of two treatment groups (split mouth design). In the effect group selected teeth were slightly separated with a flattened wedge. Subsequently, 15 % HCl-gel (pre-product; DMG, Hamburg, Germany) was applied onto the lesion surface for using a foil applicator and here-after rinsed off with water spray. The lesion was dried with ethanol and an infiltrant (pre-product; DMG, Hamburg, Germany) was applied for using a foil applicator according to manufacturers instructions. After removing surplus material the resin was light-cured and applied for a second time. In the control group a placebo treatment was performed. All subjects received instructions for flossing and brushing with fluoridated toothpaste. After 18 month the subjects were examined by an investigator who was blinded with regard to treatment. Standardized x-rays were obtained and analyzed using digital subtraction radiography.

Results

At baseline caries risk [mean (SD)] of included subjects was 40 (22) % (Cariogram 2.01). For follow up examination all 22 subjects could be recruited. No unwanted effects such as pain, loss of vitality or staining could be observed. In the control group one lesion was cavitated and one lesion had been restored by another dentist. In the effect group three lesions (10 %) and in the control group eleven lesions (38 %) showed progression ($p < 0.008$; McNemar).

Conclusion

Infiltration of proximal carious lesions extending into inner half of enamel or outer third of dentin is an efficacious method to reduce lesion progression.

Source:

Paris S, Meyer-Lueckel H. Resin Infiltration of Caries Lesions: an Efficacy Randomized Trial. *J Dent Res* 2010, 89 (8):823–826

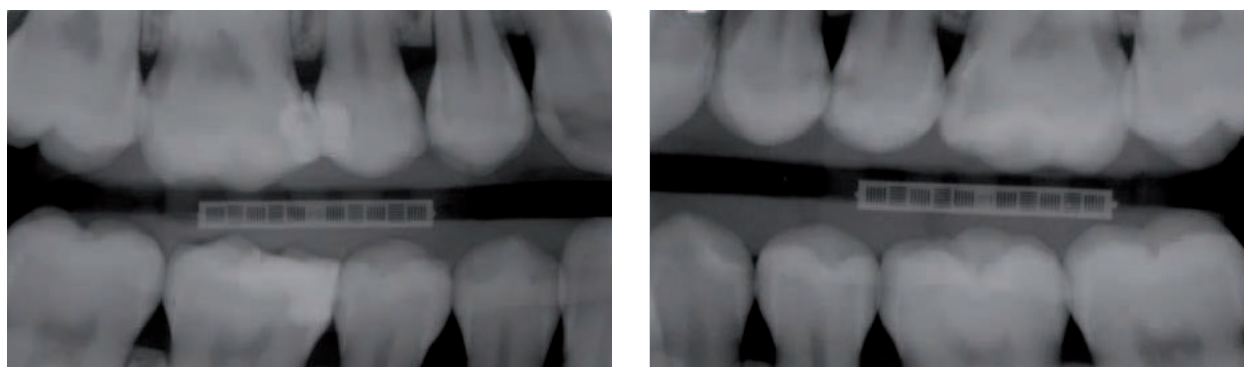


Illustration 1+2: Representative bite wing x-ray using a customized, three-dimensionally supported film holder.

Modern detection, assessment and treatment of initial proximal lesions

Martignon S¹, Meyer-Lückel H², Tellez M¹, Paris S².

¹Caries Research Unit UNICA, Dental Faculty, Universidad El Bosque, Bogotá, Colombia

²Department of Operative Dentistry and Periodontology, Christian-Albrechts-Universität, Kiel, Germany

Proper diagnosis and treatment of proximal lesions radiographically located around the enamel-dentin-junction (EDJ) have been a challenge for the clinician. A 3-year split-mouth study on proximal-posterior surfaces is being conducted to compare the efficacy of three preventive-procedures (flossing-instructions, sealing-technique, infiltrating-technique) on such lesions.

Objectives

To describe: 1.-A novel infiltration-technique. 2.-The ICDAS-II-criteria and the activity-status of proximal lesions in this sample.

Methods

Forty 16- to 31-year-olds participated each with three proximal lesions (n=120) [radiographic scores 3-radiolucency-in-the-EDJ (65 %) and 4-outer-dentinal-third (35 %)] in posterior teeth. After a 2-day elective-temporary-tooth separation elastic bands were removed and the proximal spaces cleaned. Lesions were scored with ICDAS-II criteria (0-sound, 1-first-visual-enamel-change, 2-distinctive-visual-enamel-change, 3-enamel-breakdown, 4-underlying-shadow, 5/6-distinctive/extensive-cavity) and activity criteria: -visual appearance (0-brown-opacity, 1-white-opacity, 2-surface-rupture); -plaque-stagnation area (0-no, 1-yes); -tactile findings (0-smooth/hard, 1-rough/soft). Random allocation of lesions was as follows: 40-no clinical treatment (only flossing-instructions), 40-sealing (described in: Martignon et al., Caries Res 2006), and 40-infiltration. The infiltration-procedure was conducted as follows: rubber-dam isolation, plastic-wedge placement between lesion- and neighboring-surface, positioning of a 50 µm-transparent applicator between teeth, etching of lesion-surface with 15 %-HCl-gel (120 s), water-spray (30 s), 100 %-ethanol-application (30 s), air-drying (30 s), infiltrant application (applicator; 5 min), air-drying (excesses removal, 30 s), light-curing (60 s), infiltrant reapplication (1 min), light-curing (60 s), and surface-polishing (polishing-strips).

Results

Lesions were scored as first-visual-enamel-change (0.8 %), distinctive-visual-enamel-change (89.2 %), enamel-breakdown (5.8 %), and no-assessment-possible (4.2 %). Regarding activity, visual appearance corresponded to white-opacity (65.8 %), surface-rupture (25.0 %), brown-opacity (4.2 %), and no-assessment-possible (4.2 %); tactile findings corresponded to rough (46.7 %), smooth (23.3 %) and no-assessment-possible (30.0 %). All lesions (100.0 %) were located in plaque-stagnation areas.

Conclusion

Most radiolucencies around the EDJ were visually classified as distinctive-visual-enamel-change (white-spot lesions) in plaque-stagnation areas and rough. The infiltration technique has been described as a clinically feasible method for treating these lesions.

Supported by DMG, Hamburg, Germany.

Source:

Martignon S, Meyer-Lückel H, Tellez M, Paris S. Modern Detection, Assessment and Treatment of Initial Proximal Lesions. J Dent Res 88 (Spec Iss A): 1617 (2009)

Progression of active initial-proximal lesions after infiltration, sealing or flossing-instructions

Martignon S¹, Tellez M¹, Ekstrand KR², Lara JS¹, Gomez J¹, Cortes A¹.

¹Caries Research Unit UNICA, Dental Faculty, Universidad El Bosque, Bogota, Colombia

²Dental School, University of Copenhagen, Copenhagen, Denmark

Objectives

Efficacy of three treatment strategies for initial-proximal caries lesions (A-Infiltration; B-Sealing; C-Flossing-instruction) on 40 young adults was assessed by means of a split-mouth design. To determine the progression of lesions detected as active at baseline, by radiographic examination after one year.

Methods

120 proximal lesions with radiographic extension around the enamel-dentin-junction (R-3) or in the dentine outer-third (R-4) were selected. Baseline standardized x-rays of all selected lesions were taken. Lesions were then visually assessed after using orthodontic spacers over 48 h by one examiner (SM) using ICDAS visual criteria for severity. Activity of lesions was assessed with following parameters: Plaque-stagnation area (1-no; 3-yes); Visual appearance (1-brown-spot lesion; 3-white-spot lesion; 4-surface breakdown/shadow/cavitation); Tactile feeling (2-smooth; 4-rough); Papilla bleeding (0-no; 1-yes) [Ekstrand et al.: Oper Dent 2007;32(3):225-35]. A lesion was judged for activity when all parameters were examined and was considered active when the sum of points was 8 or more. Then lesions were randomly allocated to one of the three treatment strategies. After one year standardized radiographs were taken and a blind examiner (JG) analyzed lesion progression using pair-wise reading and subtraction radiography.

Results

Activity was assessed in 85/117 lesions followed-up after one year (72.6 %); in 32 cases visual or tactile access of lesions was not achievable. Of these, 26/27 group A, 27/28 group B, and 25/27 group C lesions were assessed as active at baseline. The number of active lesions that progressed based on the paired radiograph reading was as follows: A-5, B-7, and C-13. By subtraction radiography, the numbers were 12, 19 and 19, respectively. χ^2 tests showed significant differences in lesion progression both with the pair-wise- ($\chi^2=20.7$; $P<0.000$) and subtraction-reading ($\chi^2=43.6$; $P<0.000$) methods among the three groups.

Conclusion

Less active initial lesions progressed after one year, when infiltrated than when sealed or given flossing instructions.

Source:

Martignon S, Tellez M, Ekstrand K, Lara JS, Gomez J, Cortes A. Progression of Active Initial-proximal Lesions After Infiltration, Sealing or Flossing-instructions. J Dent Res 89 (Spec Iss A): 2519 (2010)

Radiographic comparison of lesion progression after infiltration, sealing and floss instructions in a high caries risk population – 12 and 24 months follow-up

Martignon S¹, Ekstrand KR², Lara JS¹, Gomez J¹, Cortes A¹.

¹Caries Research Unit UNICA, Dental Faculty, Universidad El Bosque, Bogotá, Colombia

²Dental School, University of Copenhagen, Copenhagen, Denmark

Objective

The aim of this split-mouth design study was to assess the efficacy of resin infiltration of proximal carious lesions after one and two years.

Methods

In each of 40 patients, three proximal lesions with radiographic extension around the enamel-dentin junction or in the outer third of the dentin were selected. Lesions were randomly allocated to one of three treatment groups and all three group teeth were separated using an orthodontic spacer over 24 h. According to the treatment group allocation teeth were treated: A. Infiltration using the Kit for Infiltration (DMG, Hamburg, Germany); B. Sealing using Prime Bond NT (Dentsply, USA), following manufacturer's instructions for use; C. Control group: placebo treatment. All subjects received instructions for flossing. At 12 and 24 months follow up examinations were conducted by a blind examiner in 39 (97.5 %) and 38 (95 %) subjects, respectively. Standardized x-rays were obtained and analyzed using independent and pair-wise comparison of radiographs. At baseline subject's caries risk was distributed as follows: 45 %-low; 30 %-moderate; 20 %-high; and 5 %-very high (Cariogram 2.01).

Results

The following table shows the 1- and 2-year independent and pair-wise radiographic assessment of progression cases.

| Group | Independent reading | | Pair-wise reading | |
|------------------|---------------------|-------------------|-------------------|-------------------|
| | 1-yr vs. baseline | 2-yr vs. baseline | 1-yr vs. baseline | 2-yr vs. baseline |
| | n = 39 | n = 38 | n = 39 | n = 38 |
| A (Infiltration) | 3 | 5 | 7 | 10 |
| B (Sealing) | 2 | 5 | 11 | 15 |
| C (Control) | 5 | 10 | 19 | 24 |

Significant differences in lesion progression were observed by pair-wise reading between Infiltration and Control groups after 1 and 2 years (McNemar's test; P-values < 0.05).

Conclusion

The infiltration of proximal caries is an efficacious method to reduce lesion progression in vivo.

Source:

Martignon S, Ekstrand KR, Lara JS, Gomez J, Cortes A. 2-Year Radiographic Results of Proximal-Caries Lesions' Infiltration, Sealing and Flossing-instructions. Data on file, 2010. DMG, Hamburg, Germany

Radiographic progression of infiltrated caries lesions in vivo

Study in progress, not yet published.

Peters MC¹, Nedley M², Davis WJ², Bayne SC¹.

¹Department of Cariology, Restorative Sciences and Endodontics, School of Dentistry, University of Michigan, Ann Arbor, MI, USA

²Division of Dentistry/Otolaryngology, Medical Center, Health Science Campus, The University of Toledo, Toledo, OH, USA

Objectives

The objectives of the investigation are to study the long-term clinical performance of resin-infiltrated teeth in a caries-active environment. We hypothesize that in a high caries-risk population and with a regular preventive regimen as control management the infiltration of early proximal caries lesions leads to arrest of the lesion and reduction of lesion progression.

The micro-invasive infiltration of caries lesions may postpone and reduce the need for operative treatment more effectively than the standard-of-care preventive approaches (improved oral hygiene, diet counseling and adjunct fluoride measures).

Methods

This prospective, randomized controlled trial (RCT) investigates, in a split-mouth design, the clinical performance of resin-infiltration as early caries management. In a high caries-risk population of young volunteers (14 – 36 years old) the incidence and rate of radiographic progression of infiltrated early caries lesions will be compared to lesions managed by a standard preventive regimen. The infiltration was performed using the infiltration kit currently available on the market. Clinical evaluations are supplemented by annual bitewing radiographs after 1, 2 and 3 years. At baseline and each follow-up visit a complete oral exam is complemented with standard-of-care oral hygiene measures. The study teeth are evaluated by independent calibrated examiners, blinded to the treatment. Standardized digital bitewing radiographs are taken and evaluated by visual comparison and subtraction radiography. A total of 45 patients (45 infiltration and 45 control teeth) will be enrolled.

Status

The first radiographic follow-up evaluation will be available in December 2011.

Source:

Peters MC, Bayne SC. Radiographic Progression of Infiltrated Caries Lesions in-vivo. 2010, Data on file. DMG, Hamburg, Germany

Treatment of proximal superficial caries lesions on primary molar teeth with resin infiltration and fluoride varnish versus fluoride varnish only: efficacy after 1 year

Ekstrand KR¹, Bakshandeh A¹, Martignon S².

¹Dental School, University of Copenhagen, Copenhagen, Denmark

²Caries Research Unit UNICA, Dental Faculty, Universidad El Bosque, Bogotá, Colombia

Objectives

This split-mouth study aimed to assess the efficacy of resin-infiltrated lesions covered by fluoride varnish (FV) versus FV treatment only of proximal lesions on deciduous molar teeth. The study lasted for 1 year. Children with 2 or more superficial proximal lesions on deciduous molar teeth detected on bitewing radiographs were included.

Methods

After written parental consent, two lesions in each of 50 children were randomly allocated to one of two treatments: resin infiltration followed by FV (2.26 % F) application (test lesion) versus only FV (control lesion). The ICDAS scores of the selected lesions were recorded by 2 clinicians before the treatments (weighted kappa for inter- and intra-examiner agreement > 0.79). FV was applied to both test and control lesions 6 and 12 months after the first treatment. After 1 year ICDAS scores were obtained for 42 children and radiographs for 39. One external examiner not familiar with the study scored the radiographs twice (weighted kappa 0.88).

Results

Baseline mean age of the children was $7.17 \pm (\text{SD}) 0.68$ and mean def-s was $8.1 \pm (\text{SD}) 6.9$. After 1 year the ICDAS scores of 31 % of the test lesions and 67 % of the control lesions had progressed ($p < 0.01$). Radiographically, 23 % of the test lesions and 62 % of the control lesions had progressed ($p < 0.01$).

Conclusion

Thus, the clinical and radiographic therapeutic effect of both resin infiltration/FV over FV alone was >35 % and significant. To conclude, resin infiltration in conjunction with fluoride varnish seems promising for controlling proximal lesion progression on deciduous molar teeth.

Supported by DMG, Hamburg, Germany.

Source:

Ekstrand KR, Bakshandeh A, Martignon S. Treatment of Proximal Superficial Caries Lesions on Primary Molar Teeth with Resin Infiltration and Fluoride Varnish versus Fluoride Varnish Only: Efficacy after 1 Year. *Caries Res* 2010, 44(1): 41-46

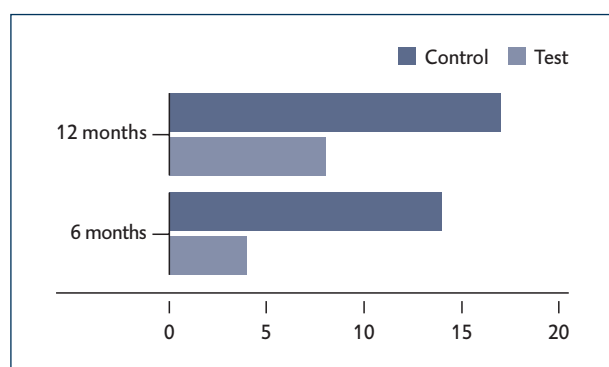


Illustration 1: Clinical cavitations after 6 and 12 months.

Clinical applicability and safety of resin infiltration of proximal caries

Alkilzy M, Splieth CH.

Department of Preventive and Pediatric Dentistry, Ernst-Moritz-Arndt-Universität, Greifswald, Germany

Objectives

The aim of this prospective practice-based study is to evaluate the applicability and clinical safety of a new minimally invasive treatment for proximal initial carious lesions by infiltration.

Methods

Five dentists in the Department of Preventive and Pediatric Dentistry/University of Greifswald applied the infiltration material Icon (DMG, Hamburg, Germany) on proximal initial lesions (D1 – D3 without cavitation on standardized X-ray) in primary and permanent teeth in 20 patients (9 m, 11 f; mean age 18.5 years \pm 8.2). The applicability was evaluated using two questionnaires filled out by dentists and patients. The dentist's questionnaire evaluated the medical history, caries experience and risk, time and difficulties of application, involvement of neighboring teeth and the comparison to a composite filling. The patient questionnaire evaluated the satisfaction with the procedure regarding time, comfort and complexity. At the recall after one week, the infiltrated surfaces were assessed for discoloration, marginal adaptation, gingival status and plaque accumulation. The recall ended with an oral hygiene instruction including flossing and topical fluoride application. The results showed good patient's satisfaction with the procedure and time (mean time 24.3 min \pm 4.95) which included rubber dam application (mean time 9 min \pm 2.8) and infiltration (mean time 15.3 min \pm 4.4).

Results

In four patients, the proximal spaces were insufficient due to difficulties with the separation of the teeth, which prolonged the infiltration time. In most cases, the dentists reported that infiltration was comparable to the application of a composite filling. At recalls, all infiltrated surfaces showed smooth transition to enamel, no discoloration, and no undesirable inflammatory or allergic signs in the adjacent gingiva.

Conclusion

In conclusion, the infiltration of carious initial lesions may provide a simple, minimally invasive procedure for treatment of proximal initial caries.

Supported by Stiftung Innovative Zahnmedizin, Switzerland.

Source:

Alkilzy M, Splieth C. Clinical applicability and safety of resin infiltration of proximal caries. *Caries Res* 44: 171–248, Abs. 49, (2010)

The evaluation of resin infiltration for masking labial enamel white spot lesion

Kim S, Shin JH, Kim E, Lee SY, Yoo SG.

School of Dentistry, Pusan National University, Pusan, Korea

Objectives

The aim of this study was to clinically assess the effectiveness of masking white spot enamel lesions with resin infiltration technique which was recently developed to arrest the incipient caries in a minimum invasive concept.

Methods

Twenty teeth with DDE (Developmental Defect of Enamel) from twelve children and eighteen teeth with POD (Postorthodontic Decalcification) from nine children were selected and treated with resin infiltration. The clinical procedure was composed of erosion with HCL, desiccation with ethanol and application of low-viscosity light cured infiltrant resin. The standardized photos were taken before, immediately after and one week after treatment, analyzed with image analyzing software calculating ΔE value.

Results

The results were classified into 3 groups: completely masked; partially masked; not changed. Among twenty teeth with DDE, five teeth (25 %) were classified as completely masked whereas seven (35 %) and eight teeth (40 %) showed partially masked and not changed respectively. Among eighteen teeth with POD, eleven teeth (61 %) showed completely masked, six teeth (33 %) partially masked and one tooth (6 %) not changed. In some teeth, the result was more improved after 1 week than immediately after infiltration. Conclusively, masking effect was dramatic in some cases, while totally or partially not in other cases. It was thought that the effect depends on lesion depths; namely, in the lesions deeper than penetration range of infiltrant resin, the masking effect was a little or none.

Conclusion

The method for clinically measuring lesion depths was thought highly desirable to distinguish the indication of resin infiltration for masking purpose. In this study Icon treatment led to good esthetic results at teeth with postorthodontic decalcification.

Source:

Kim S, Shin JH, Kim EY, Lee SY, Yoo SG. The evaluation of resin infiltration for masking labial enamel white spot lesions. *Caries Res* 44: 171–248, Abs. 47, (2010)

Clinical performance and color stability of infiltrated smooth surface lesions (post-orthodontic white spots)

Study in progress, not yet published.

Phark JH^{1,2}, Duarte S^{1,2}.

¹Department of Comprehensive Care, School of Dental Medicine, Case Western Reserve University, Cleveland, OH, USA

²Division of Restorative Sciences, School of Dentistry, University of Southern California, Los Angeles, CA, USA

Objectives

The aim of this split-mouth design study was to compare the efficacy of infiltration vs. fluoridation of post-orthodontic white spot lesions (WSL).

Methods

41 lesions pairs with post-orthodontic WSLs on the facial smooth surfaces of canines and premolars were enrolled in this study according to eligibility criteria. Orthodontic brackets had been removed from those teeth 1-3 months ago. WSLs were randomly assigned to the test (infiltration: Icon, DMG, Hamburg, Germany) and control group (fluoridation: Fluor Protector, Ivoclar). Treatment of teeth was performed according to manufacturers' recommendations. Size of the white spot lesions and their colorimetric parameters were assessed by digital photographs and spectrophotometric analysis before treatment, after treatment, and after 1, 6, 12, 18, and 24 months. Furthermore, impressions were taken for assessment of changes in surface integrity. For visual and digital evaluation of the changes in white spot lesion size, images were taken using a digital SLR camera system (Nikon D300, Nikon). Imaging conditions were controlled as much as possible to ensure optimum clarity and reproducibility. Before taking pictures the assigned teeth were cleaned using pumice and rubber polishing cups, then thoroughly rinsed with water and air dried for 15 seconds. Pictures were analyzed using an image analysis software (ImageJ, NIH). Size of the white spot lesion (W) and the whole facial tooth surface (T) were measured, then W:T-ratio (in %) was calculated. For evaluation of the color stability L*a*b* values of the lesion and the whole tooth were obtained, using a spectrophotometer (Crystaleye, Olympus), to calculate Delta E.

Results

Statistical evaluation was performed for using one-way ANOVA for Delta E values and Kruskal-Wallis and Mann-Whitney tests for the lesion size. The 6-months data for color stability show no significant difference in Delta E for the control (3.30 ± 1.75) and test group (3.77 ± 2.13). W:T ratio decreased significantly after using the test treatment from 15.38 % before to 10.17 % after the treatment ($p < 0.05$) and remained stable after 1 month (9.55 %) and 6 months (8.20 %) ($p > 0.05$). For the control group WSL size remained stable (18.94 % before, 20.16 % after treatment) and decreased just slightly ($p > 0.05$) during follow up (15.47 % after 1 month, 13.14 % after 6 months).

Conclusion

Resin infiltration reduces post-orthodontic white spot lesions effectively in-vivo and does not discolor more than the control group.

Source:

Phark JH, Duarte S. Clinical performance and color stability of infiltrated smooth surface lesions. 2010, Data on file. DMG, Hamburg. Germany

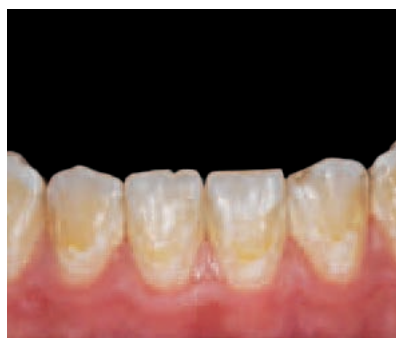

Illustration 1: Typical white-spot lesions after debanding.

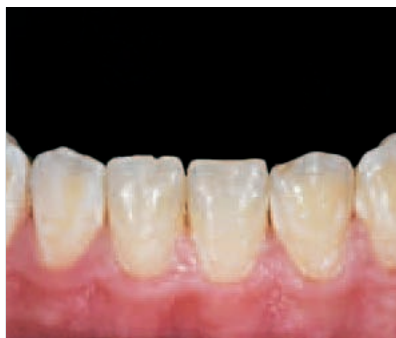

Illustration 2: Clinical appearance directly after infiltration treatment.

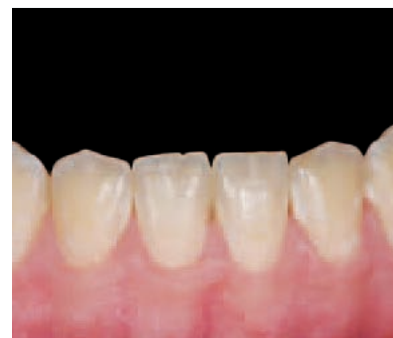

Illustration 3: Color stable white-spot lesions one month after infiltration treatment.

Progression of non-cavitated caries lesions: Efficacy of caries infiltration compared to sealing

Study in progress, not yet published.

Anauate Netto C, Amore R, di Hipólito V, Perlatti D'Alpino PH.

Dental School, Universidade dos Bandeirantes (UNIBAN), São Paulo, SP, Brazil

Objective

Fissure sealing has been proven to be an effective treatment in preventing caries formation or caries progression in occlusal surfaces. This study is designed to prove efficacy in hampering lesion progression of a novel caries infiltration technique in comparison to sealing of lesions.

Methods

40 young patients between 8 to 18 years will be enrolled in this study. Occlusal caries is diagnosed according to ICDAS standard: 0-sound, 1-first-visual-enamel-change, 2-distinctive-visual-enamel-change, 3-enamel-breakdown, 4-underlying-shadow, 5/6-distinctive/extensive-cavity) and activity criteria: -visual appearance (0-brown-opacity, 1-white-opacity, 2-surface-rupture); -plaque-stagnation area (0-no, 1-yes); -tactile findings (0-smooth/hard, 1-rough/soft) and calibrated with Diagnodent Pen® (Kavo, Biberach, Germany). Cavitations are excluded by tactile probing. Included lesions are located in permanent molars. Individual caries risk is assessed using the Cariogram software. Bitewing radiographs are taken at baseline and at the follow-up visits after 6, 12, 24 and 36 months. The teeth to be treated are randomly assigned in a split-mouth design to two groups: group A –Sealing (Alpha Seal®, DFL, Brazil) and group B – Icon (DMG, Hamburg, Germany). Materials are used according to manufacturers instructions. The lesions are judged at each follow up visit regarding lesion progression, surface integrity and plaque stagnation. To assess surface integrity impressions are taken at baseline and each follow-up visit. Replicas are made and surface integrity is assessed by means of light microscopy and SEM.

Status

The radiographic follow up data after 6 months are available in February 2011.

This study is sponsored by DMG, Germany.

Source:

Anauate Netto C, Amore R, di Hipólito V, Perlatti D'Alpino PH. Progression of not cavitated caries lesions: Efficacy of caries infiltration compared to sealing. 2010, Data on file. DMG, Hamburg, Germany

Infiltration versus microabrasion for cosmetic treatment of white spot lesion due to orthodontic treatment

Study in progress, not yet published.

Coelho Leal S¹, Faber J¹, Hilgert L¹, Ekstrand KR².

¹School of Dentistry, Health Science Center, Universidade de Brasília (UnB), Brasília, DF, Brazil

²Dental School, University of Copenhagen, Copenhagen, Denmark

Objectives

White spot lesions might occur during the orthodontic treatment due to plaque accumulation on the enamel surfaces adjacent to fixed appliance. The aims of the study are: 1) To compare the cosmetic results of two techniques for white spots lesions removal due to orthodontic treatment 2) To assess patients' level of satisfaction regarding the comfort and clinical results obtained through the two techniques.

Methods

Twenty individuals varying from 14 to 16 years old who had recently concluded the orthodontic treatment (within the last 30 days) will be invited to participate in the study. A split-mouth design is used, all participants will receive both treatments: hydrochloric acid-pumice microabrasion (treatment A) and infiltration (Treatment B). The teeth 11 and 12 or 21 and 22 will be randomly allocated to each of the treatments. The patients will be submitted to a professional prophylaxis immediately after the removal of orthodontics appliance, followed by a fluoride varnish application (Duraphat - Colgate®). The same procedure will be repeated once a week, until 4 sessions of varnish is performed in order to remineralize those areas that are prone to cavitate. In order to assess the level of removal of mineral due to the treatments, and the clinical effectiveness of the methods, photographs and impressions are taken at baseline and each follow up visit. The pictures will be used to measure the percentage of the tooth buccal surface that is affected by the opacity. For that reason, a software program Paint Shop Pro 7.0 will be used to delimit the opacity total area while the Image Pro Express 4.0 will be used to calculate the total area.

Status

Study is in progress. Six months results of all volunteers are expected in February 2011.

Source:

Coelho Leal S, Faber J, Hilgert L, Ekstrand K. Infiltration versus microabrasion for cosmetic treatment of white spot lesion due to orthodontic treatment. 2010, Data on file. DMG Hamburg, Germany

Durability of esthetic improvement following white spot lesion treatment with the Icon infiltration system

Study in progress, not yet published.

Knösel M, Eckstein A, Jung K.

Department of Orthodontics, Dental School, Georg-August-Universität, Göttingen, Germany

Objective

To assess the 6-month durability of esthetic improvement of white spot lesions (WSL) achieved with a novel infiltrant (Icon; DMG, Hamburg, Germany) in comparison to untreated white spot lesions.

Methods

30 subjects with WSL after multibracket treatment were recruited for lesion infiltration with prior enamel conditioning with a 20 % HCl gel. Treatment of WSL was performed in a split-mouth design on front teeth of either quadrants one and three, or two and four, while the other two were used as control. Group designation was randomized. CIE-L*a*b* data were assessed using a spectrophotometer prior to infiltration treatment (T0), and after one day (T1), one week (T2), four weeks (T3), three months (T4) and six months (T5) weeks from baseline (T0). Notification was made of necessary number of conditioning intervals, and adjusted to the existence / persisting of the WSL.

Intermediate Results

Lesion infiltration using the Icon infiltrant improves the esthetic appearance of demineralised teeth. Results show an adequate durability over 6 months. Longer existing WSL require higher numbers of conditioning intervals.

Status

Study is in progress. Six months results of all volunteers are expected in December 2010.

Source:

Knösel M, Eckstein A, Jung K. Durability of esthetic improvement following white spot lesion treatment with the Icon infiltration system. 2010, Data on file. DMG, Hamburg, Germany

Infiltration concept – List of literature

- Bratthall D, Hänsel-Petersson G, Stjernsvard J. Manual de Cariograma. 2004 [online]; Available from: URL: <http://www.db.od.mah.se/car/cariogramainfo.html>.
- Bjørndal L. Dentin caries: Progression and clinical management. *Oper Dent* 2002;27:211-7.
- Bjørndal L, Thylstrup A. A structural analysis of approximal enamel caries lesions and subjacent dentin reactions. *Eur J Oral Sci* 1995;103:25-31.
- Bjørndal L, Mjör IA. Dental caries: Characteristics of lesions and pulpal reaction. In: Mjör IA, editor. *Pulp-dentin Biology in Restorative Dentistry*. Chicago: Quintessence Publishing Co. Inc; 2002. p. 55-76.
- Bille J, Thylstrup A. Radiographic diagnosis and clinical tissue changes in relation to treatment of approximal carious lesions. *Caries Res* 1982;16:1-6.
- Bighton D, Brailsford S, Samaranyake LP, Brown JP, Ping FX, Grant-Mills D, et al. A multi-country comparison of caries-associated microflora in demographically diverse children. *Community Dent Health* 2004;21(1 Suppl):96-101.
- Bönecker M, Cleaton-Jones P. Trends in Dental Caries in Latin American and Caribbean 5-6- and 11-13-year-old Children: A Systematic Review. *Community Dent Oral Epidemiol* 2003;31:152-7.
- Bruun C, Ekstrand KR, Andreasen KB. A new in vitro method for testing the interproximal cleaning potential of toothbrushing. *J Clin Dent* 1998;9(1):11-5.
- Buchanan H, Niven N. Validation of a facial Image scale to assess child dental anxiety. *Int J Paediatr Dent* 2002;12(1):47-52.
- Buonocore MG. A simple method of increasing the adhesion of acrylic filling materials to enamel surfaces. *J Dent Res* 1955;34:849-53.
- Carvalho JC, Thylstrup A, Ekstrand KR: Results after 3 Years of Non-Operative Occlusal Caries Treatment of Erupting Permanent First Molars. *Community Dent Oral Epidemiol* 1992;20:187-92.
- Chadwick BL, Dummer PHM. Factors affecting the diagnostic quality of bitewing radiographs: a review. *Br Dent J* 2000;184(2):80-4.
- Ekstrand KR, Martignon S, Ricketts DJ, Qvist V. Detection and activity assessment of primary coronal caries lesions: a methodologic study. *Oper Dent* 2007 May-Jun;32(3):225-35.
- Ekstrand KR, Ricketts DNJ, Kidd EAM. Occlusal Caries: Pathology, Diagnosis and Logical Management. *Dent Update* 2001;28:380-7.
- Ekstrand KR, Kuzmina IN, Kuzmina E, Christiansen MEC. Two and a half-year outcome of caries-preventive programs offered to groups of children in the Solntsevsky District of Moscow. *Caries Res* 2000;34:8-19.
- Ekstrand KR, Martignon S, Ricketts DJN, Qvist V. The Validity of a Classification System for Clinical Activity Assessment of Primary Coronal Caries Lesions. *Caries Res* 2005;39(4):Abstract No. 38.
- Ekstrand KR, Brunn G, Bruun M. Plaque and gingival status as indicators for caries progression on approximal surfaces. *Caries Res* 1998b;32:41-5.
- Ekstrand KR, Bjørndal L. Structural analysis of plaque and caries in relation to the morphology of the groove-fossa system on erupting mandibular third molars. *Caries Res* 1997;31:336-48.
- Ellwood R, Fejerskov O. Clinical use of fluoride. In: Fejerskov O, Kidd E, editors. *Dental Caries: The Disease and its Clinical Management*. Copenhagen: Blackwell Munksgaard; 2003. p. 189-222.
- Fejerskov O, Thylstrup A. Pathology of dental caries. In: Thylstrup A, Fejerskov O, editors. *Textbook of cariology*. Copenhagen: Munksgaard; 1986. p. 204-34.
- Fejerskov O. Concepts of dental caries and their consequences for understanding the disease. *Community Dent Oral Epidemiol* 1997;25:5-12.
- Fejerskov O. Changing paradigms in concepts on dental caries: Consequences for oral health care. *Caries Res* 2004;38:182-91.
- Fehr von der FR, Loe H, Theilade E. Experimental caries in man. *Caries Res* 1970;4:131.

-
- Gomez SS, Basili CP, Emilson CG. A 2-year clinical evaluation of sealed noncavitated approximal posterior carious lesions in adolescents. *Clin Oral Investig* 2005 Dec;9(4):239-43.
 - Going RE, Loesche WJ, Grainger DA, Syed SA. The viability of microorganisms in carious lesions five years after covering with a fissure sealant. *J Am Dent Assoc* 1978;97:455-62.
 - Gray GB, Shellis P. Infiltration of resin into white spot caries-like lesions of enamel: An In vitro study. *Eur J Prosthodont Restor Dent* 2002;10(1):27-32.
 - Handelman SL. Therapeutic use of sealants for incipient or early carious lesions in children and young adults. *Proc Finn Dent Soc* 1991;87(4):463-75.
 - Holmen L, Thylstrup A, Øgaard B, Kragh F. A scanning electron microscopic study of progressive stages of enamel caries in vivo. *Caries Res* 1985b;19:348-54.
 - Kidd EAM, Fejerskov O. What constitutes dental caries? Histopathology of carious enamel and dentin related to the action of cariogenic biofilms. *J Dent Res* 2004;83 (Spec Iss C):35-8
 - Koch G, Arneberg P, Thylstrup A. Oral hygiene and dental caries. In: Thylstrup A, Fejerskov O, editors. *Textbook of Clinical Cariology*. 2nd ed. Copenhagen: Munksgaard; 1994. p. 219-30.
 - International Caries Detection and Assessment System Workshop, Baltimore 12-14th March 2005. Sponsored by the NIDCR, the ADA, and the IADR.
 - Ismail A., Woosung S. The Impact of Universal Access to Dental Caries on Disparities in Caries Experience in Children. *J Am Dent Assoc* 2001;132:295-303.
 - Petersen PE, Bourgeois D, Ogawa H, Estupinan-Day S, Ndiaye C. The global burden of oral diseases and risks to oral health. *Bull World Health Organ* 2005;83(9):661-9.
 - Lang NP. Commonly used indices to assess oral hygiene and gingival and periodontal health and diseases. In: Lang NP, Attström R, Löe H, editors. *Proceedings of the European Workshop on Mechanical Plaque Control*. Berlin: Quintessenz Verlag; 1998. p. 50-71.
 - Llodra JC, Bravo M, Delgado-Rodriguez M, Baca P, Galvez R. Factors influencing the effectiveness of sealants – a meta-analysis. *Community Dent Oral Epidemiol* 1993;21:261-8.
 - Locker D, Jokovic A. The use of pit and fissure sealants in preventing caries in the permanent dentition of children. In: Kay EJ, editor. *Prevention Series. Part 8*. *Br Dent J* 2003;195(7):375-8.
 - Löe H, von der Fehr FR, Schiött CR. Inhibition of experimental caries by plaque prevention. The effect of chlorhexidine mouthrinses. *Scand J Dent Res* 1972;80:1-9.
 - Marinho VCC, Higgins JPT, Sheiham A, Logan S. Fluoride toothpastes for preventing dental caries in children and adolescents (Cochrane Review). In: *The Cochrane Library: Oxford Update Software*. Oxford: 2003. Issue 1.
 - Martignon S, Ekstrand KR, Cuevas S, Reyes JF, Torres C, Tamayo M, Bautista G. Relationship between ICDAS caries scores and histological lesion depth on proximal surfaces of primary and permanent teeth. An in vitro study. *Caries Res* 2007;41(4):290.
 - Martignon S, Ekstrand KR, Ellwood R. Efficacy of sealing proximal early active lesions: an 18-month clinical study evaluated by conventional and subtraction radiography. *Caries Res* 2006;40(5):382-8.
 - Mejäre I, Källestål C, Stenlund H. Incidence and progression of approximal caries from 11 to 22 years of age in Sweden: a prospective radiographic study. *Caries Res* 1999;33:93-100.
 - Mejäre I. Management of the advanced carious lesion in primary teeth. In: Hugoson A, Falk M, Hohansson S, editors. *Consensus Conference on Caries in the Primary Dentition and its Clinical Management*. Stockholm: Förlagshuset Gothia; 2002. p. 57-68.
 - Mertz-Fairhurst EJ, Curtis JW, Ergle JW, Rueggeberg FA. Ultraconservative and cariostatic sealed restorations: results at year 10. *J Am Dent Assoc* 1998;129:55-66.
 - Mertz-Fairhurst EJ, Schuster GS, Fairhurst CW. Arresting caries by sealants: results of a clinical study. *J Am Dent Assoc* 1986;112:194-7.

Infiltration concept – List of literature






- Meyer-Lueckel H, Paris S, Kielbassa AM. Surface layer erosion of natural caries lesions with phosphoric and hydrochloric acid gels in preparation for resin infiltration. *Caries Res* 2007;41(3):223-30.
- Meyer-Lueckel H, Paris S, Mueller J, Cölfen H, Kielbassa AM. Influence of the application time on the penetration of different dental adhesives and a fissure sealant into artificial subsurface lesions in bovine enamel. *Dent Mater* 2006 Jan;22(1):22-8. Epub 2005 Jul 25.
- Meyer-Lueckel H, Mueller J, Paris S, Renz H, Kielbassa AM. The penetration of various adhesives into initial enamel lesions. *Caries Res* 2004a;38(4):388.
- Meyer-Lueckel H, Paris S, Mueller J, Hummel M, Hopfenmueller W, Kielbassa AM. Progression of sealed initial enamel lesions after in vitro demineralization. *Caries Res* 2004b;38(4):403.
- Ministerio de Salud - República de Colombia, Centro Nacional de Consultoría – CNC. Estudio Nacional de Salud Bucal. In: Ministerio de Salud - República de Colombia, Centro Nacional de Consultoría – CNC: III Estudio Nacional de Salud Bucal - ENSAB III; Tomo VII. Bogotá: Lito Servicios ALER; 1999.
- Mueller J, Meyer-Lueckel H, Paris S, Hopfenmueller W, Kielbassa AM. Inhibition of lesion progression by the penetration of resins in vitro: influence of the application procedure. *Oper Dent* 2006 May-Jun;31(3):338-45.
- Nyvad B. The role of oral hygiene. In: Fejerskov O, Kidd EAM, editors. *Dental caries: The Disease and its Clinical Management*. Copenhagen: Blackwell Munksgaard; 2003. p. 171-7.
- Paris S, Meyer-Lueckel H, Cölfen H, Kielbassa AM. Resin infiltration of artificial enamel caries lesions with experimental light curing resins. *Dent Mater J* 2007 Jul;26(4):582-8.
- Paris S, Meyer-Lueckel H, Kielbassa AM. Resin infiltration of natural caries lesions. *J Dent Res* 2007 Jul;86(7):662-6.
- Paris S, Meyer-Lueckel H, Cölfen H, Kielbassa AM. Penetration coefficients of commercially available and experimental composites intended to infiltrate enamel carious lesions. *Dent Mater* 2007 Jun;23(6):742-8.
- Paris S, Meyer-Lueckel H, Mueller J, Hummel M, Kielbassa AM. Progression of sealed initial bovine enamel lesions under demineralizing conditions in vitro. *Caries Res* 2006;40(2):124-9.
- Pitts NB. Monitoring of caries progression in permanent and primary posterior approximal enamel by bitewing radiography. *Community Dent Oral Epidemiol* 1983;11:228-35.
- Pitts NB. Regression of approximal carious lesions diagnosed from serial standardized bitewing radiographs. (Short Communication). *Caries Res* 1986;20:85-90.
- Pitts NB, Longbottom C. Temporary tooth separation with special reference to diagnosis and preventive management of equivocal approximal carious lesions. *Quintessence Int* 1987;18:563-73.
- Pitts NB, Rimmer PA. An in vivo comparison of radiographic and directly assessed clinical caries status of posterior approximal surfaces in primary and permanent teeth. *Caries Res* 1992;26:146-52.
- Pitts N. "ICDAS" – an international system for caries detection and assessment being developed to facilitate caries epidemiology, research and appropriate clinical management. *Community Dent Oral Epidemiol* 2004;21:131-6.
- Pitts NB, Stamm JW. International consensus workshop on caries clinical trials (ICW-CCT) – Final consensus statements: Agreeing where the evidence leads. *J Dent Res* 2004;83(Spec Iss C):35-8.
- Rimmer PA, Pitts NB. Temporary elective tooth separation as a diagnostic aid in general dental practice. *Br Dent J* 1990;169:87-92.
- Robinson C, Brookes SJ, Kiskham J, Word SR, Shore RC. In vitro studies of the penetration of adhesive resins into artificial caries-like lesions. *Caries Res* 2001;35:136-41.
- Schwartz M, Gröndahl H-G, Pliskin S, Boffa J. A longitudinal analysis from bite-wing radiographs of the rate of progression of approximal carious lesions through human dental enamel. *Arch Oral Biol* 1984;29(7):529-36.

-
- Scottish Intercollegiate Guidelines Network (SIGN). Preventing Dental caries in children at high caries risk. Targeted prevention of dental caries in the permanent teeth of 6-16 year olds presenting for dental care. A national clinical guideline [online]. December 2000; Available from: URL: <http://www.SIGN.AC.UK>.
 - Scottish Intercollegiate Guidelines Network Guideline: Prevention and management of dental decay in the pre-school child. A national clinical guideline. Edinburgh: Scottish Intercollegiate Guideline Network; 2005.
 - Siegel S, Castellan NJ Jr. The case of one sample, two measures or paired replicates. In: Siegel S, Castellan NJ Jr., editors. Nonparametric Statistics for the Behavioral Sciences. 2nd ed. Singapore: McGraw-Hill International Editors; edition, 2002. p. 73-101.
 - Silverstone LM. Structure of carious enamel, including the early lesion. In: Melcher AH, Zarb GA, editors. Dental enamel. Development, structure and caries. Oral Sciences Reviews. Volume III. Copenhagen: Munksgaard; 1973. p. 100-60.
 - Simonsen RJ. Pit and fissure sealants. In: Simonsen RJ, editor. Clinical Applications of the Acid Etch Technique. Chicago: Quintessence Publishing Co Inc; 1978. p. 19-42.
 - Swift EJ Jr. El efecto de sellantes en caries dentales: una revisión. J Am Dent Assoc 1988;116:700-4.
 - Thylstrup A, Bille J, Qvist V. Radiographic and observed tissue changes in approximal caries lesions at the time of operative treatment. Caries Res 1986;20:75-84.
 - Thylstrup A, Qvist V. Principal enamel and dentine reactions during caries progression. In: Thylstrup A, Leach SA, Qvist V, editors. Dentine and Dentine Reactions in the Oral Cavity. Oxford: IRL Press; 1987. p. 3-16.
 - Thylstrup A, Bruun C. The use of dentifrices in the treatment of dental caries. In: Embery G, Rølla G, editors: Clinical and Biological Aspects of Dentifrices. Oxford: Oxford University Press; 1992. p. 131-43.
 - Thylstrup A, Birkeland JM. Prognosis of caries. In: Thylstrup A, Fejerskov O, editors. Textbook of Clinical Cariology, ed 2. Copenhagen: Munksgaard; 1994. p. 383-92.
 - Thylstrup A, Fejerskov O. Clinical and pathological features of dental caries. In: Thylstrup A, Fejerskov O, editors. Textbook of clinical cariology, ed 2. Copenhagen: Munksgaard; 1994. p. 111-58.
 - Thylstrup A, Bruun C, Holmen L. In vivo caries models- Mechanisms for caries initiation and its arrestment. Adv Dent Res 1994;8(2):144-57.
 - Thylstrup A. When is caries caries, and what should we do about it? Quintessence Int 1998;29(9):594-8.
 - Van Meerbeek B, Vargas M, Inoue S, Yoshida Y, Peumans M, Lambrechts P, Vanherle G. Adhesives and cements to promote preservation dentistry. Oper Dent 2001; Suppl 6:119-44.
 - Weintraub JA. The effectiveness of pit and fissure sealants. J Public Health Dent 1989;49(Spec Iss):317-30.
 - Wenzel A, Pitts N, Verdonchot EH, Kalsbeek H. Developments in radiographic caries diagnosis. J Dent 1993;21:131-40.
 - WHO. Global oral health databank. National Oral Health Information Clearinghouse. Oral health database OMS [online]. 2002. Available from: URL: <http://www.nohic.nih.gov/data.html>.

Bitewing diagnosis and indications for infiltration

| Proximal infiltration | Smooth surface infiltration |
|--|------------------------------|
| Radiographic extension up to the outer third of dentin | Active enamel caries lesions |
| No detectable cavitation | No detectable cavitation |
| Dry working field achievable | Dry working field achievable |
| Lesion progression likely | Esthetic impairment |

The indications for the infiltration include lesions with extension up to D1.

| Scores | | Criteria |
|--------|---|---|
| E1 |  | Radiolucency confined to the outer half of enamel. |
| E2 |  | Radiolucency in the inner half of the enamel including lesions extending up to but not beyond the enamel-dentin junction. |
| D1 |  | Radiolucency in the dentin; beyond enamel-dentin junction but within the outer third of dentin. |
| D2 |  | Radiolucency with obvious extension into the second third of dentin. |
| D3 |  | Radiolucency with obvious extension into the inner third of dentin. |

Radiographic scores to classify the depth of proximal carious lesions (based on: Mejäre et al. 1999)

Source:

Mejäre I, Källest IC; Stenlund H. Incidence and progression of approximal caries from 11 to 22 years of age in Sweden: A prospective radiographic study. Caries Res. 1999;33(2):93-100.

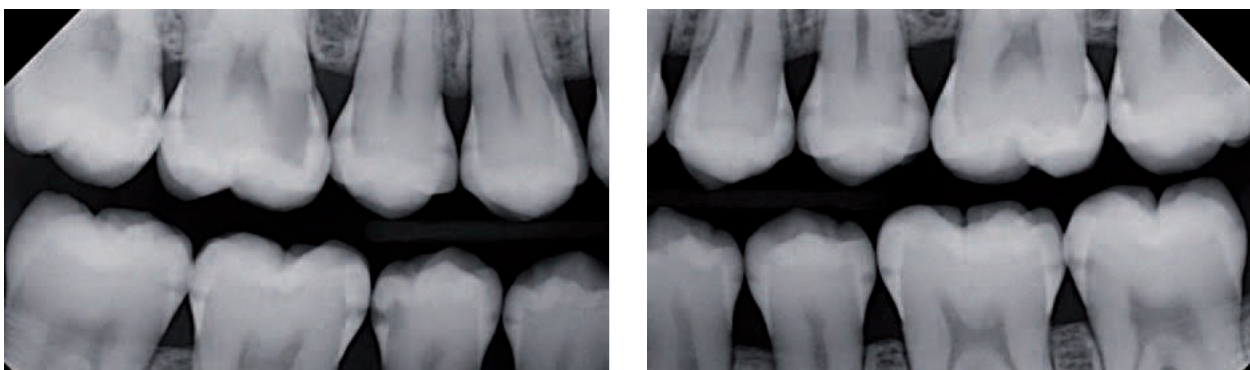


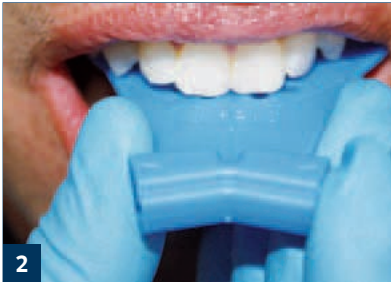Illustration 1+2: Radiograph of lesion extension.

Clinical use – X-ray holder system

The success of the caries infiltration depends on proper detection and diagnosis of caries. The use of a customized X-ray device is beneficial in X-ray diagnostics and follow-up investigation to monitor the lesion progression. This system consists of a individual bite plate, that is customized using bite registration material and a mountable film holder containing a grid. Thus, taking X-rays becomes reproducible and monitoring caries lesions more valid.



1
Place patient upright in the X-ray unit



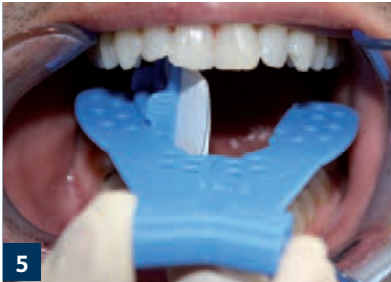2
Select size



3
Mount film holder



4
Seat in X-ray film or foil respectively



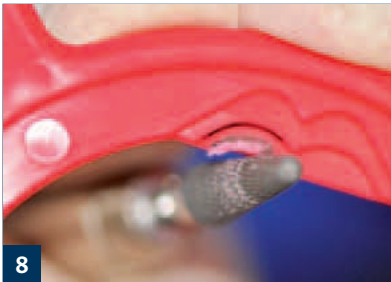5
Check fit




6
Apply bite registration on bite plate



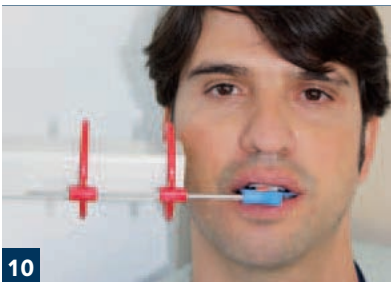
7
Occlusal stops in molar and incisor region



8
Adjust aiming rings to X-ray tube



9
Use two aiming rings

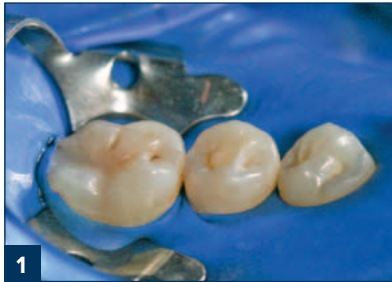

10
Take the X-ray

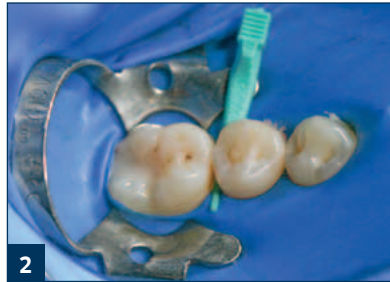Clinical case: Dr. Susanne Effenberger, Hamburg, Germany

Clinical use – proximal surfaces

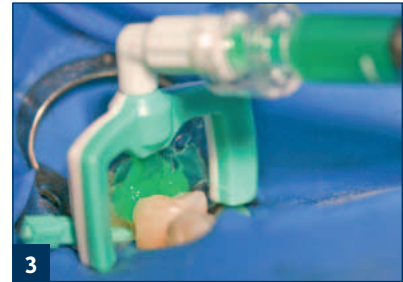Sufficient tooth separation is a key factor for the clinical success of the caries infiltration. Specially designed wedges are placed between the teeth to be treated and after approximately 30 s the applicators can be placed. The green side of the applicator is placed facing the surface to be treated. Through the perforations of the applicator's foil bag the material is applied on the lesion. The white side protects the neighboring surface.



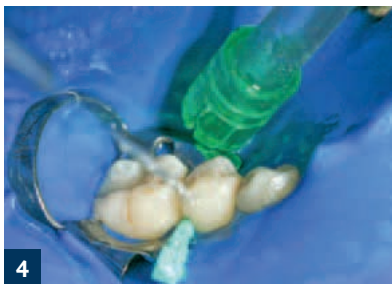1 Place rubber dam



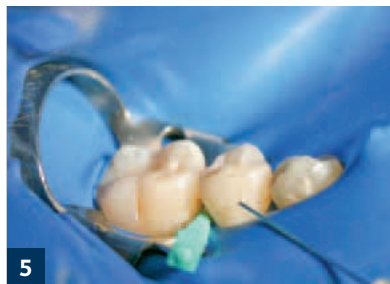2 Place wedge for temporary tooth separation



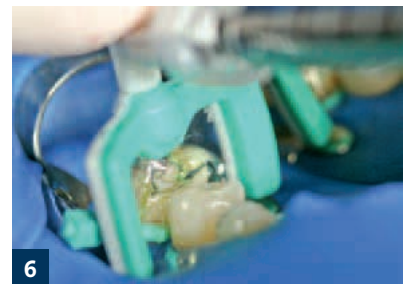3 Apply Icon-Etch for 2 min



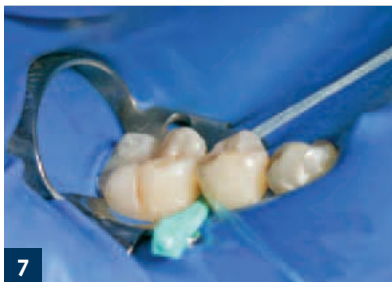4 Remove Icon-Etch with water spray



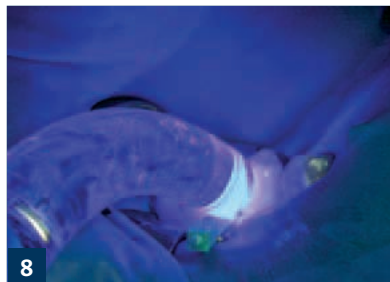
5 Apply Icon-Dry and dry with air



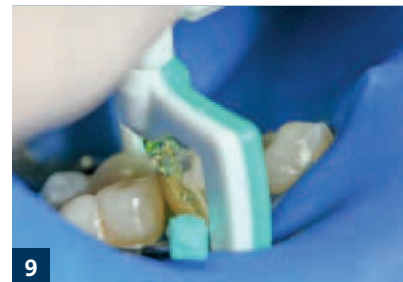6 Apply Icon-Infiltrant for 3 min



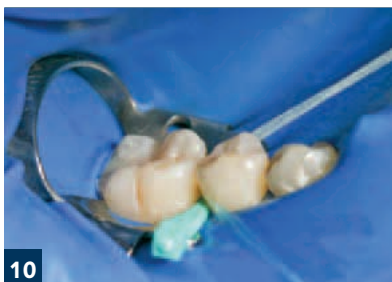7 Remove excess



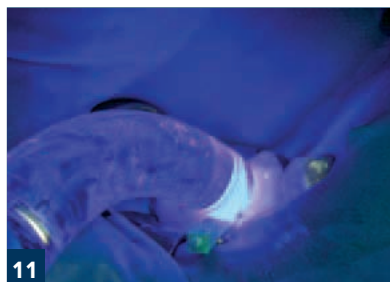
8 Light-cure for 40 sec



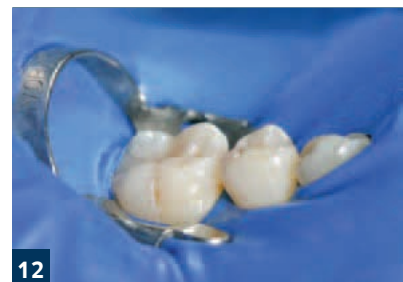9 Reapply Icon-Infiltrant for 1 min



10 Remove excess



11 Light-cure for 40 sec

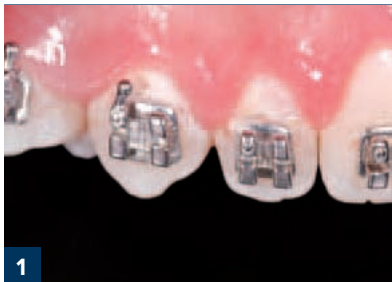

12 Clean the treated surface and remove excess

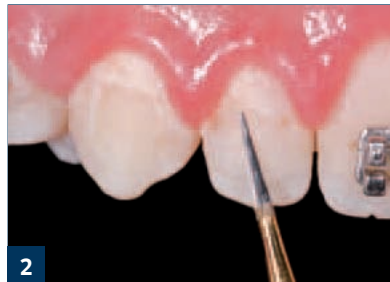Clinical case: Prof. Dr. Marcio Garcia dos Santos, São Paulo, Brazil

Clinical use – vestibular surfaces

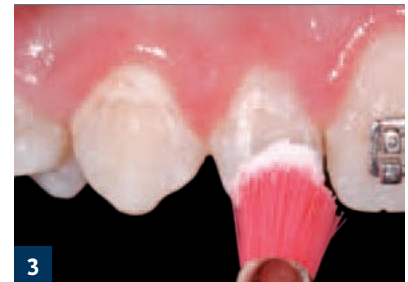White spot lesions, as they occur frequently after orthodontic treatment, can be masked effectively by caries infiltration. The refractive index (RI) of the infiltrant resin is optimized and adapted to the RI of sound enamel. The lesion is masked. In case the whitish appearance of the lesion remains during the drying step, it is recommended to repeat the etching procedure up to two more times.



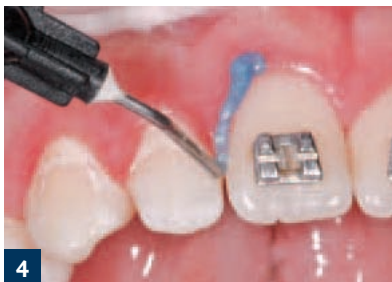1
Initial situation



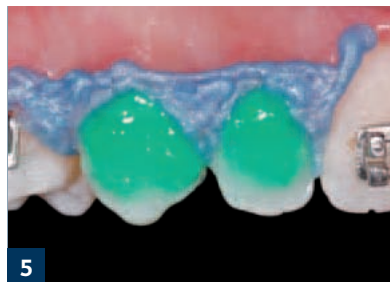2
Clean surface



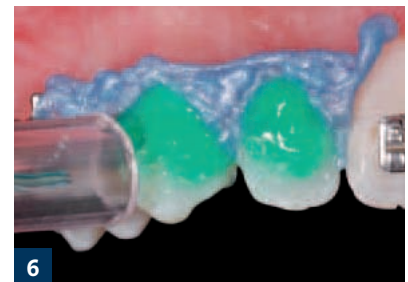3
Polish with polishing paste



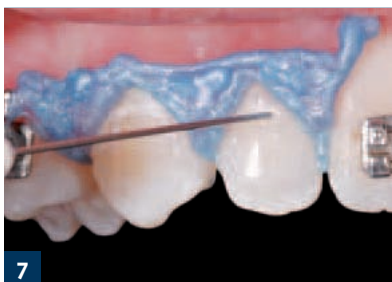4
Apply isolation (rubber dam or gingival barrier)



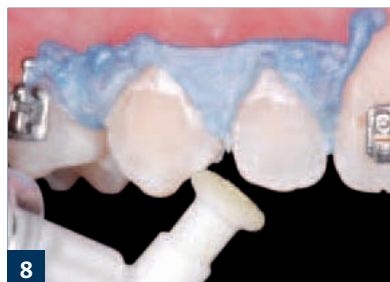5
Apply Icon-Etch for 2 min



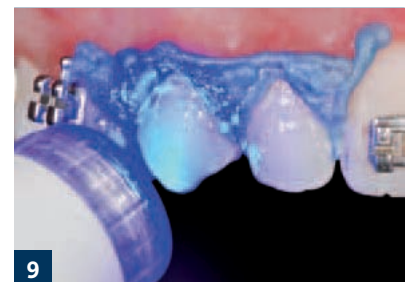6
Remove Icon-Etch



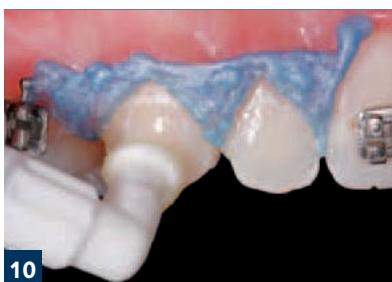7
Apply Icon-Dry and dry with air



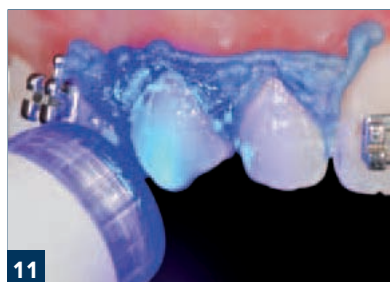8
Apply Icon-Infiltrant for 3 min



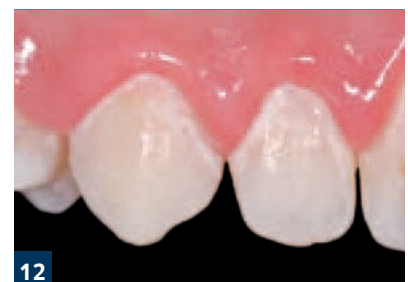9
Light-cure for 40 sec



10
Reapply Icon-Infiltrant for 1 min



11
Light-cure for 40 sec



12
Final result after polishing

Hints and tricks for daily practice

Dr. Susanne Effenberger, Hamburg, Germany

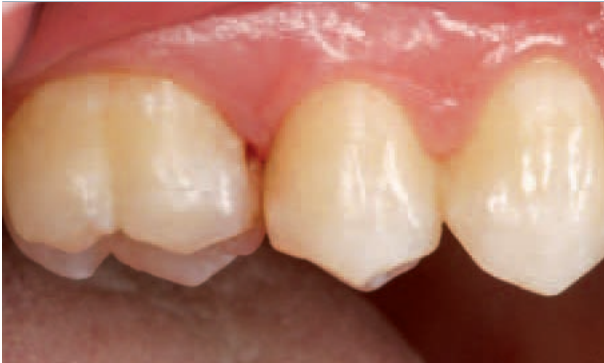

Illustration 1: Cavitated lesion on 16 mesial.

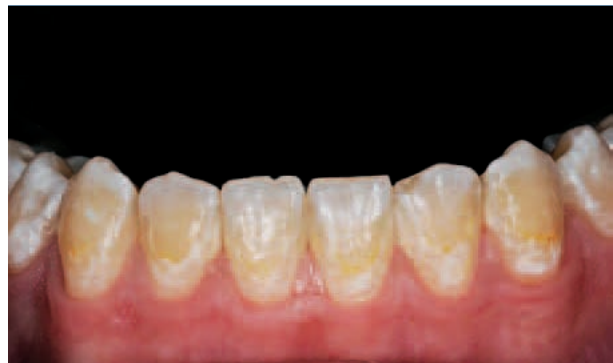

Illustration 2: Typical appearance and localization of carious white spot lesions.

Diagnosis and treatment guidelines

Patient's history

1. Assessment of the patient's caries experience and the patient's current caries risk.
2. Assessment of oral hygiene status and fluoride use.
3. Assessment of nutritional habits, particularly sugar consumption.

Visual/tactile diagnosis

1. Clean the teeth: removal of discolorations and hard and soft deposits.
2. Maintain optimal light conditions for visual inspection.
3. Assessment of the tooth surfaces for structural changes, opacities, surface gloss.
4. Dry the tooth surfaces with air and reassess the quality of the surfaces.
5. The assessment of the quality of the surfaces is done after separation, without pressure using a fine explorer. This will allow even the smallest non-homogeneous areas and micro-cavities to be "felt".
6. In the event of vestibular lesions, localization and the moment at which they are established are essential indicators for the lesion being carious. Carious lesions are mostly localized in the cervical and central coronal third and develop over the course of time e.g. during orthodontic treatment as a result of insufficient oral hygiene or life episodes with insufficient nutritional and/or oral hygiene habits.
7. Assessing the activity of the cavity. Signs and symptoms of active lesions:
 - bright color
 - opaque, matte appearance
 - surface is rough
 - plaque retention on the surface

X-ray diagnosis

1. Selection of an appropriate bite-wing holder.
2. If possible, use a customized X-ray holder, as this makes it possible to check the progression much more accurately.
3. Position the patient sitting upright in the X-ray unit.
4. Align the tube precisely.
5. When taking the full dental row series, use one exposure for the premolar region and one for the molar region respectively.
6. For findings using the X-rays, whenever possible, use earlier exposures as a comparison.

Isolation of the working field

1. Position the rubber dam proximally.
2. Isolate enough of a working area. The mesial and distal neighboring teeth should also be isolated.
3. Proximal ligatures of dental floss or 4.0 suture material help to keep the rubber dam cervically positioned and to seal the sulcus.
4. Put a vestibular rubber dam in place whenever possible.
5. Sufficient isolation: at least 3 out of 3 in the incisor area, or preferably 4 out of 4.
6. Ligatures of dental silk or suture material should be used to fix the rubber dam at the cervical region of the tooth. Vestibular lesions are mostly to be found in the central and cervical thirds of the crown, so that white cervical edges will frequently be left behind if the isolation is not sufficient.
7. Alternatively, a liquid dam or gingival barrier can be used in the incisor region. Care should then be taken that the dam is applied precisely and no shreds of the material should lie on the surfaces of the tooth.

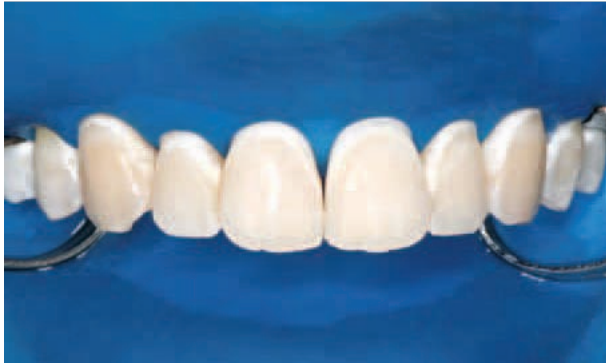

Illustration 3: Isolation using rubber dam and fixation by ligatures.

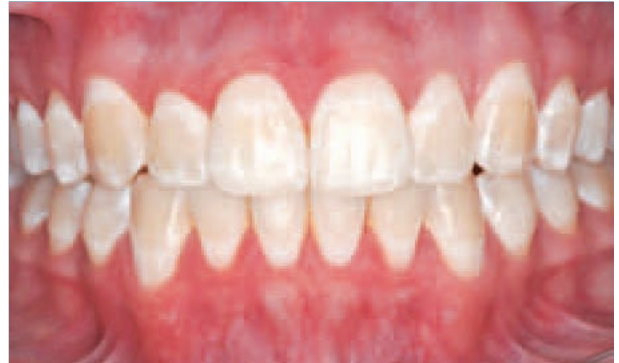

Illustration 5: Before treatment with Icon.

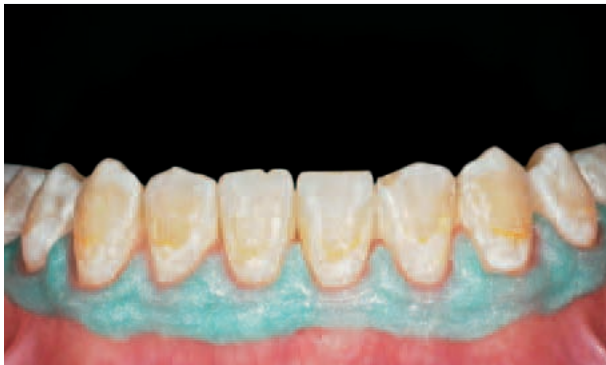

Illustration 4: Isolation using liquid rubber dam.

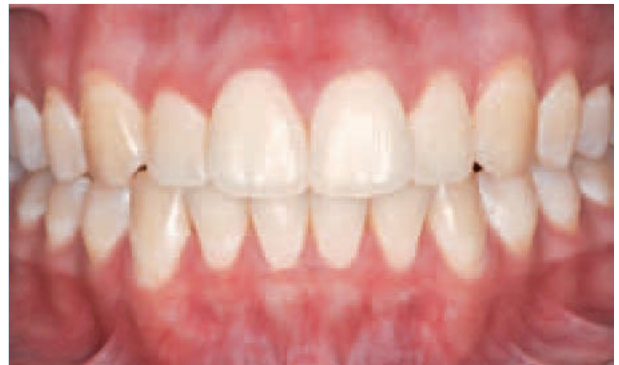

Illustration 6: Immediately after treatment with Icon.

8. The following procedure has proven its value in practice: apply the liquid dam using a cannula with a large gauge from the mucogingival border up to approx. 1 mm (0.04") from the neck of the tooth. The cannula is then swapped for one with a small gauge and the remaining strips are filled in up to the neck of the tooth.

After the material has hardened, any excess can be removed with a fine scaler.

This process allows you to envisage precisely what degree of cosmetic success the treatment will have. The drying steps should then be repeated.

4. If the white appearance of the lesion persists after water penetration, the etching step can be repeated up to two times. For particularly persistent discolorations, the etching gel can be mixed with pumice powder; the etching gel can then be activated when applied, i.e. applied with gentle pressure throughout the reaction time using a circular motion.

Clinical procedure – vestibular

Vestibular infiltration

1. Follow the instructions for use.
2. The dental surfaces are cleaned with polishing paste.
3. After the drying step with air, an intermediate check can be carried out to see if the etching step has been successful. To have a preview of the esthetic result, either Icon-Dry or water can be applied to the lesion, which then should diminish significantly.

Hints and tricks for daily practice

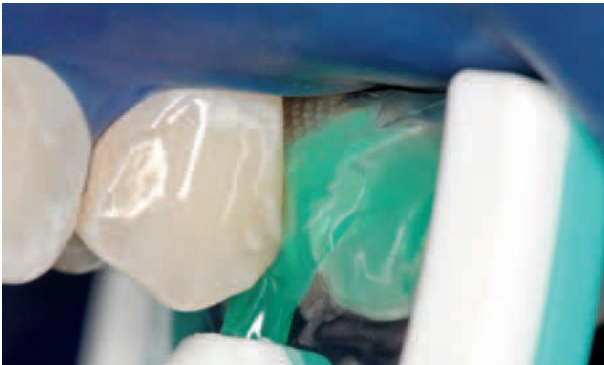

Illustration 7: Proximal applicator.

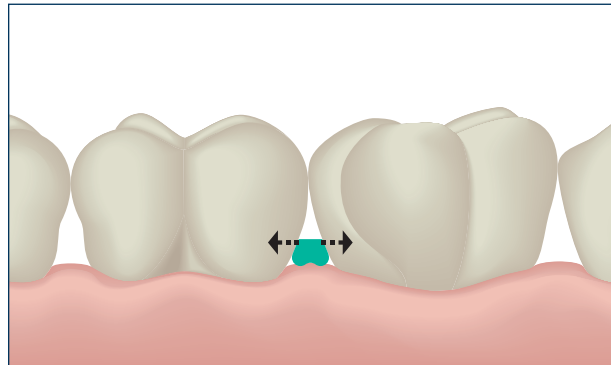


Illustration 9: Wedge used for tooth separation.

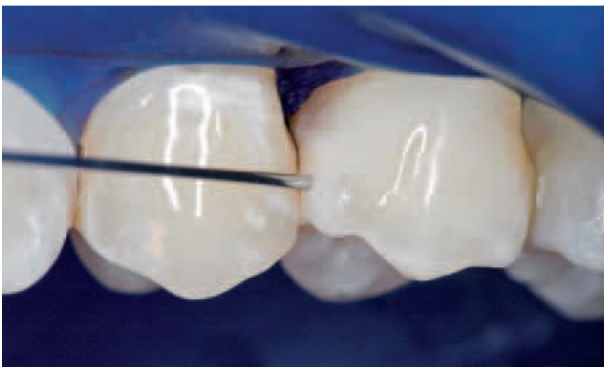


Illustration 8: Drying step.

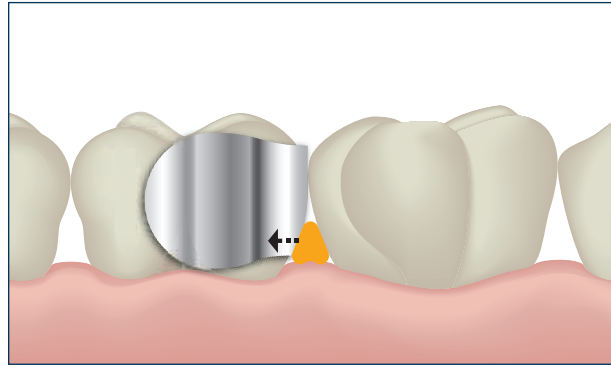


Illustration 10: Wedge used to fix a matrix.

Clinical procedure – proximal

Separation

1. For temporary separation of the teeth, the specially developed separation wedges that are provided with the product are ideal. Alternatively, in exceptional cases, wooden wedges, orthodontic molar rubber rings or separators can be used.
2. Insert the separator wedges straight, slowly and with an even pressure until the first resistance. The wedge is held in this position for a few seconds and then inserted further, slowly and evenly, into the interdental space. After about 30 seconds, sufficient separation to allow treatment will be obtained.
3. In rare cases, the patient will experience discomfort during this separation process. This can be relieved by local anesthesia.

Proximal infiltration

1. Follow the instructions for use.
2. The dental surfaces are cleaned with dental floss.
3. The applicators are inserted evenly and slowly into the interdental space. When doing so, take care that the foils are not bent and the perforated green side is facing the spot that is to be treated.
4. After application, any excess of the material can be removed with the small suction unit. Excess etching gel can be removed with water spray. An excess of the infiltrant can be removed with air spray.
5. After placing the applicators, the wedge can be activated, i.e. loosened a little, so that the foil is fixed in place in the proximal space. Before removal of the applicators, the wedge is inserted further into the proximal space again and the teeth are separated further. The applicators can then be removed easily.

Separating teeth in the proximal area

Sufficient separation (approximately 50 – 80 μm) of the teeth in the proximal area is required for the successful Icon treatment. Below, we would like to provide you with some helpful information.

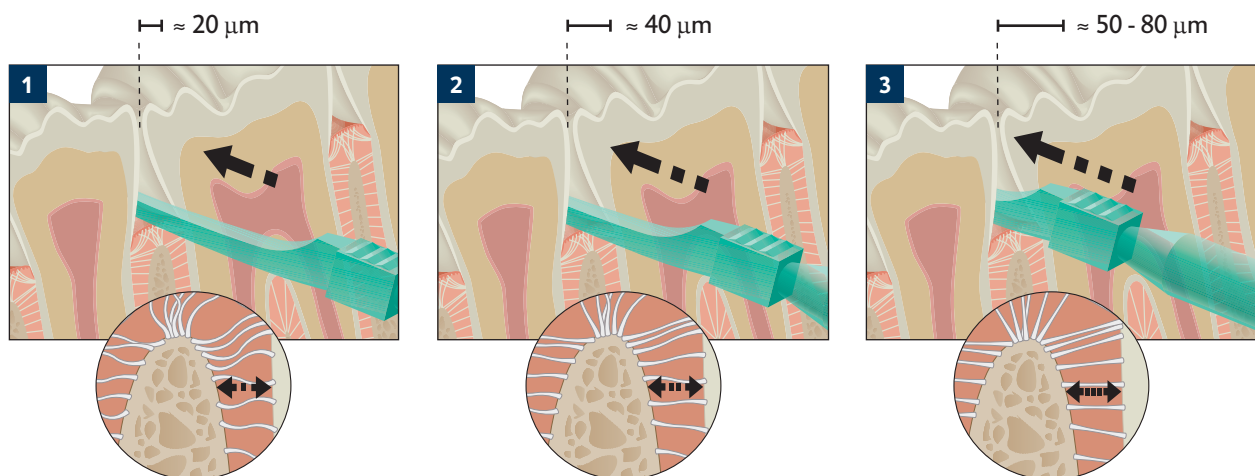
The individual teeth are suspended between the tooth root and the alveolar bone on so-called Sharpey's fibers. They are part of the mineralized tissue and help anchor the tendons and ligaments.

When the teeth are separated, these fibers stretch and give out a stimulus perceived as pressure if the teeth are crowded, unless anesthesia was administered first. Therefore, adequate expansion and as a result adequate separation of the teeth requires some time – similar to a muscle stretch – and should be performed gradually.

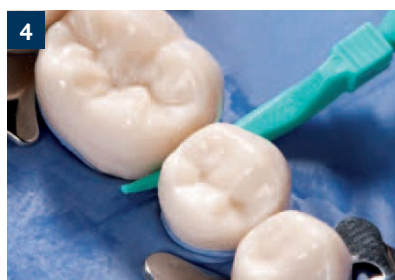
The special dental wedges included in the proximal Icon packages have been optimized for this treatment with respect to the application of force. The leveled shape ensures good reachability of the area (lesion) to be treated with the proximal tip. This is not always the case with alternative separation systems (e.g. wooden wedges which swell when exposed to saliva). In contrast to the filling therapy, the wedge is not used to fix the matrix band but for separation.

During the first step of the separation, the wedge should be applied into the gap between the teeth until an initial resistance is noticeable. The patient will perceive this procedure as light pressure. The position of the wedge is maintained for several seconds to stretch Sharpey's fibers. Then, the wedge is pushed in further until the widest part of the wedge achieves an adequate separation. In doing so, please make sure that the applied wedge does not get jammed.

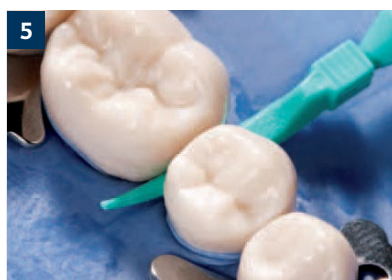
For extreme crowding, the procedure described above may need to be repeated.



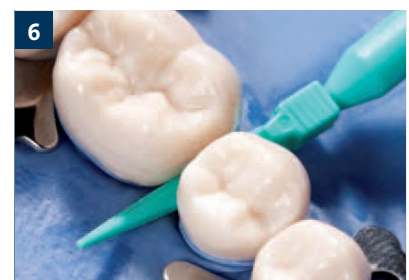Illustrations 1 – 3 show the gradual separation of teeth (approx. 20; 40; 50 – 80 μm). The magnified areas display the gradual stretching of Sharpey's fibers. The gradual insertion of the wedge will stretch the fibers and separate the teeth.



4 Insert the wedge until first resistance is noticeable.



5 Gradually insert the wedge further...



6 ... until sufficient separation with the wedge is achieved.

Portfolio

Icon – Practice-oriented product solutions for an innovative treatment method

DMG converted the scientific findings on caries infiltration into a user-friendly product for daily use at the dental office. Or more specifically: into intelligent product solutions for different applications.

Icon – proximal

With Icon – proximal DMG mastered the challenge to give dentists efficient access to critical proximal areas. Icon – proximal enables the treatment of proximal carious lesions with a maximum radiologically visible extent into the outer third of the dentine without drilling. A slight separation of the teeth is sufficient to apply the required materials directly to the desired area using a special Proximal-Tip made from ultra thin film. The result: a pleasant treatment for the patient with nearly no hard tissue loss or loss of the natural tooth shape. Icon – proximal is offered in clearly arranged treatment units. One unit contains all necessary materials for a successful infiltration treatment of two proximal lesions each in a patient. A user-friendly designed treatment tray ensures the proper execution of the work steps in the correct order.



Illustration 1: Proximal-Tip

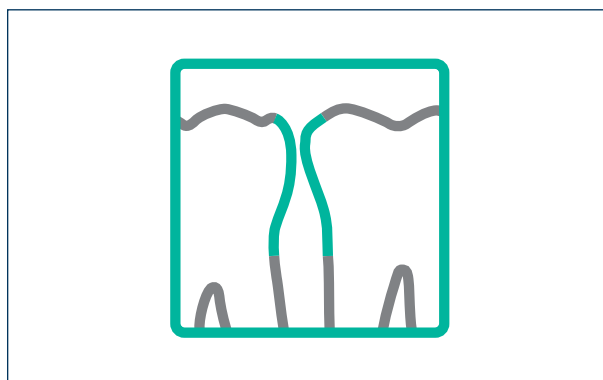


Illustration 2: Designed for proximal infiltration

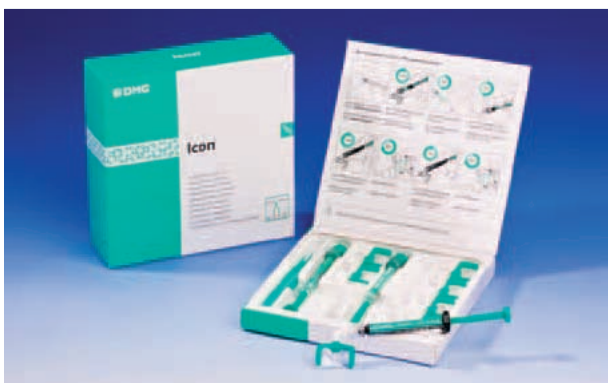

Illustration 3: Proximal treatment tray



Illustration 4: Packaging unit – Cube proximal

Icon – smooth surfaces

Other important areas of application for caries infiltration are incipient carious lesions on easily accessible smooth surfaces. These undesired cariogenic “white spots” can easily and efficiently be treated with Icon – smooth surfaces. Icon – smooth surfaces combines the cosmetic challenge with the medically sensible early arrest of carious lesions. Naturally, the product specifically developed for vestibular applications also offers the advantages of the user-friendly tray arrangement. Special Vestibular-Tips ensure the successful treatment of cariogenic white spots with maximum conservation of the hard tissue. The results impress after only one sitting.

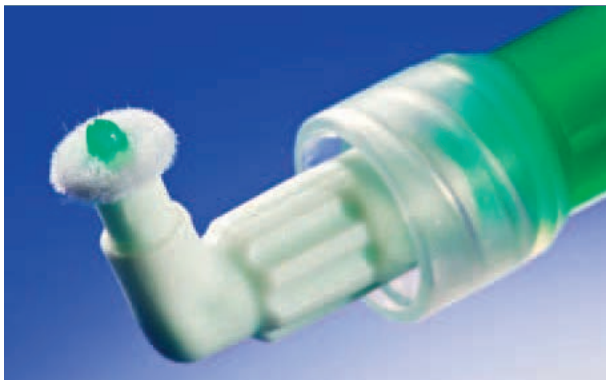

Illustration 1: Vestibular-Tip

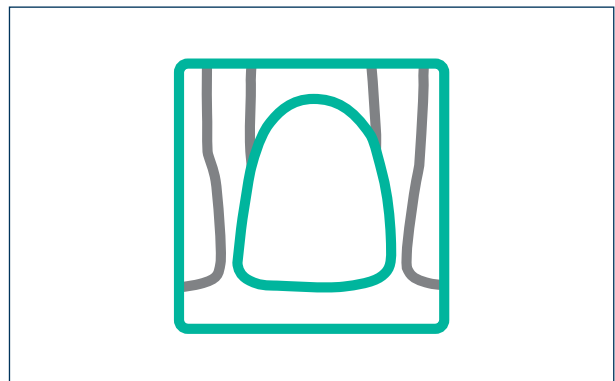


Illustration 2: Designed for smooth surface infiltration

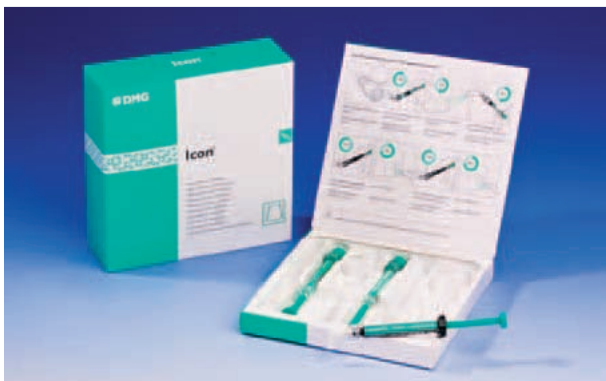

Illustration 3: Smooth surface treatment tray



Illustration 4: Packaging unit – Cube smooth surface

Authors



Dr. med. dent. Mohammad Alkilzy, DDS

- 1992 – 1997 Dentistry, University of Aleppo, Aleppo, Syria
- 1997 Doctor Dental Surgeon, University of Aleppo, Aleppo, Syria
- 1998 – 2000 Postgraduation course in Pediatric Dentistry, University of Damascus, Damascus, Syria
- 2000 Specialist in Pediatric Dentistry, University of Damascus, Damascus, Syria
- 2000 – 2003 Assistant Professor, Department of Pediatric Dentistry, University of Aleppo, Aleppo, Syria
- since 2003 Assistant Professor, Department of Preventive and Pediatric Dentistry, Ernst-Moritz-Arndt-Universität, Greifswald, Germany
- 2009 PhD, Ernst-Moritz-Arndt-Universität, Greifswald, Germany



Prof. Dr. Paulo D'Alpino, DDS, MSc, PhD

- 1987 – 1991 Dentistry, Universidade de São Paulo (USP), Baurú, SP, Brazil
- 2000 – 2005 MSc, PhD in Dentistry, Universidade de São Paulo (USP), Baurú, SP, Brazil
- 2003 – 2004 Research Fellowship, Medical College of Georgia, Augusta, GA, USA
- 1994 Specialisation programme in Public Health
- since 2009 Professor, Clinic of Primary Care, Universidade dos Bandeirantes (UNIBAN), São Paulo, SP, Brazil
- since 2009 Researcher, Study group "Dentistry", Universidade dos Bandeirantes (UNIBAN), São Paulo, SP, Brazil



Prof. Dr. Ricardo Amore, DDS, MSc, PhD

- 1984 – 1988 Dentistry, Universidade de Mogi das Cruzes (UMC), Mogi das Cruzes, SP, Brazil
- 1996 MSc in Dentistry, Universidade de Taubaté (UNITAU), Taubaté, SP, Brazil
- 2002 – 2004 MSc, PhD in Restorative Dentistry, Universidade Estadual Paulista (UNESP), São José dos Campos, SP, Brazil
- since 1998 Responsible Professor, Clinic of Primary Care, Universidade dos Bandeirantes (UNIBAN), São Paulo, SP, Brazil
- since 2007 Researcher, Study group "Dentistry", Universidade dos Bandeirantes (UNIBAN), São Paulo, SP, Brazil
- since 2009 President of the Ethics committee for Human Research, Universidade dos Bandeirantes (UNIBAN), São Paulo, SP, Brazil

Prof. Dr. Camillo Anauate Netto, DDS, MSc, PhD

- 1975 – 1978 Dentistry, Universidade de Mogi das Cruzes (UMC), Mogi das Cruzes, SP, Brazil
- 1986 Specialisation in Restorative Dentistry
- 1989 – 1992 MSc, PhD in Dentistry, Universidade de São Paulo (USP), São Paulo, SP, Brazil
- since 1998 Professor of Dentistry, Universidade dos Bandeirantes (UNIBAN), São Paulo, SP, Brazil
- 2002 Research Fellowship, Dental Materials and Operative Dentistry, University of Minnesota, Minneapolis, MN, USA
- since 2006 Coordinator of Study group “Dentistry”, Universidade dos Bandeirantes (UNIBAN), São Paulo, SP, Brazil
- since 2009 Vice-president of GBPD – “Grupo Brasileiro de Professores de Dentística”

Dr. Azam Bakhshandeh, DDS, PhD

- 2000 – 2005 Cand. odont. Dentistry, University of Copenhagen, Copenhagen, Denmark
- 2005 – 2007 Private Dentist, Copenhagen, Denmark
- 2007 Doctor of Dentistry, University of Copenhagen, Copenhagen, Denmark
- 2007 – 2010 PhD student, Dental School, University of Copenhagen, Copenhagen, Denmark

Prof. Dr. Stephen C. Bayne, MS, PhD, FADM

- 1974 MS, Biological Materials (Biomaterials), Northwestern University, Evanston, IL, USA
- 1977 – 1984 Ass/Associate Professor, Restorative Dentistry, The University of Mississippi, School of Dentistry, Jackson, MS, USA
- 1978 PhD, Biological Materials (Biomaterials), Northwestern University, Evanston, IL, USA
- 1983 Fellow, Academy of Dental Materials
- 1984 – 1992 Associate Professor, Operative Dentistry, University of North Carolina, School of Dentistry, Chapel Hill, NC, USA
- 1992 – 2005 Professor, Operative Dentistry, University of North Carolina, School of Dentistry, Chapel Hill, NC, USA
- 2005 Hollenback Prize, Academy of Operative Dentistry
- 2004 – 2009 AADR Board of Directors, President 2006-2007, International Association for Dental Research, Alexandria, VA, USA
- since 2006 Professor and Chair, Department of Cariology, Restorative Sciences and Endodontics, School of Dentistry, University of Michigan, Ann Arbor, MI, USA
- 2007 Academy of Dental Materials, Founders Award
- 2010 DMG-IADR Ryge-Mahler Clinical Research Award
- 2010 Honorary PhD, University of Athens, Athens, Greece



Authors



Prof. Dr. Laurindo Borelli Neto DDS, PhD

- 1984 – 1987** Dentistry, Universidade Paulista (UNIP), São Paulo, SP, Brazil
- 1992 – 1993** Specialisation in Periodontology, Universidade Cidade de São Paulo (UNICID), São Paulo, SP, Brazil
- 1993 – 1995** PhD in Science, Human Anatomy, Institute of Biomedical Science, Universidade de São Paulo (USP), São Paulo, SP, Brazil
- since 2003** Director of the Dentistry programme, Universidade dos Bandeirantes (UNIBAN), São Paulo, SP, Brazil
- since 1993** Professor for Periodontology, Universidade Cidade de São Paulo (UNICID), São Paulo, SP, Brazil




Andrea Büchting

- 2004 – 2009** Dentistry, Charité – Universitätsmedizin Berlin, Berlin, Germany
- since 2010** Dentist, Private Practice, Berlin-Lichtenrade, Germany
- since 2010** Postgraduate Curriculum in Pediatric Dentistry, Philipp-Pfaff-Institut, Berlin, Germany



Prof. Dr. Alessandra Bühler Borges, DDS, MSc, PhD

- 1992 – 1995** Dentistry, Universidade Estadual Paulista (UNESP), São José dos Campos, SP, Brazil
- 1999** MSc in Restorative Dentistry, Universidade Estadual Paulista (UNESP), São José dos Campos, SP, Brazil
- 2003** PhD, Universidade Estadual Paulista (UNESP), São José dos Campos, SP, Brazil
- 2003** Specialist in Public Health, Universidade de Taubaté (UNITAU), Taubaté, SP, Brazil
- since 2006** Assistant Professor, Department of Restorative Dentistry, Universidade Estadual Paulista (UNESP), São José dos Campos, SP, Brazil



Prof. Dr. John O. Burgess, DDS, MSc

- 1971 – 1975** Dentistry, School of Dentistry, Emory University, Atlanta, GA, USA
- 1980 – 1982** MSc Biomedical Sciences, University of Texas Health, Science Center, Houston, TX, USA
- 1969 – 1990** Dental Practice, US Air Force
- 1998 – 2006** Professor, Director Department of Operative Dentistry and Biomaterials, Pro-Dean Clinical Research, Louisiana State University, Health Sciences Center-School of Dentistry, New Orleans, LA, USA
- since 2006** Professor, Director Department of Prosthodontics, Pro-Dean Clinical Research, School of Dentistry, University of Alabama, Birmingham, AL, USA

Prof. Dr. Michael F. Burrow, BDS, MDS, PhD, MEd

- 1981 BDS, University of Adelaide, Adelaide, SA, Australia
- 1987 MDS, University of Adelaide, Adelaide, SA, Australia
- 1989 – 1994 PhD, Scholarship from the Japanese Ministry of Education, Culture, Sports, Science and Technology, Tokyo Medical and Dental University, Tokyo, Japan
- 2003 Master of Education, The University of Melbourne, Melbourne, VIC, Australia
- since 2007 Professor in Restorative Dentistry, Clinical Dean of the Melbourne Dental School and Restorative Dentistry Discipline Head, The University of Melbourne, Melbourne, VIC, Australia
- Visiting Prosthodontist, Royal Dental Hospital of Melbourne, Melbourne, VIC, Australia
- since 2000 Member of the Australian Delegation of the International Organization for Standardization Technical Committee 106
- since 2004 Member of the ADA's DIME Committee



Dr. med. dent. Georg Cachovan

- 1987 – 1994 Dentistry, University of Hamburg, Hamburg, Germany
- 1993 – 1994 Academic Year University of Birmingham, Dental School, Birmingham, United Kingdom
- 1994 – 1998 Private Dentist, Hamburg, Germany
- since 1998 Scientific Assistant, Department of Restorative and Preventive Dentistry, University of Hamburg, Hamburg, Germany
- 2001 Visiting researcher, University of Otago, Dunedin, New Zealand
- 2004 Visiting researcher, University of Otago, Dunedin, New Zealand



Dr. Deniz Cakir, DDS, MSc

- 1996 – 2002 Dentistry, Faculty of Dentistry, Ankara University, Ankara, Turkey
- 2002 – 2003 Private Practice, Bursa, Turkey
- 2003 – 2005 MSc Programm, School of Dentistry, University of Alabama, Birmingham, AL, USA
- since 2006 Research Associate, Lecturer, Department of Prosthodontics, School of Dentistry, University of Alabama, Birmingham, AL, USA



Patrícia Campos Ferreira da Rosa, DDS

- 2005 – 2008 Dentistry, Universidade Estadual Paulista (UNESP), São José dos Campos, SP, Brazil
- since 2009 Graduated Student, Department of Restorative Dentistry, Universidade Estadual Paulista (UNESP), São José dos Campos, SP, Brazil




Authors



Dr. med. dent. Andreas J. Chatzidakis

- 1998-2003** Dentistry, Charité – University Medicine (FU) Berlin, Germany
- since 2004** Assistant Professor, Department of Prosthodontics, Gerontostomatology and TMD, Dental School, Charité – Universitätsmedizin Berlin, Berlin, Germany
- 2007** Dr. med. dent. Charité – Universitätsmedizin Berlin, Berlin, Germany
- since 2008** Postgraduation course in Orthodontics, Master of Science (MSc), Donau-Universität Krems, Austria



Kyo Min Choo

- since 2006** Pre-professional scholar program, Case Western Reserve University, Cleveland, OH, USA
- since 2008** Dental student, Dental School, Case Western Reserve University, Cleveland, OH, USA



Prof. Dr. Soraya Coelho Leal, DDS, MSc, PhD

- 1987 – 1991** Bachelor of Dental Surgery (BDS), Dentistry, University of Uberaba (UNIUBE), Uberaba, MG, Brazil
- 1994** Certificate in Pediatric Dentistry, Universidade de São Paulo (USP), Baurú, SP, Brazil
- 1998** Master of Dental Science (MSc) in Oral Health Sciences, Universidade de Brasília (UnB), Brasília, DF, Brazil
- 2003** PhD in Oral Health Sciences, Universidade de Brasília (UnB), Brasília, DF, Brazil
- 2007** Certificate in Evidence Based Dentistry, University of Oxford, Oxford, United Kingdom
- since 1992** Private Practice, Brasília, DF, Brazil
- since 1997** Associate Professor, Brazilian Dental Association (ABO), Brasília, DF, Brazil
- since 1998** Assistant Professor, Health Science Center, School of Dentistry, Universidade de Brasília (UnB), Brasília, DF, Brazil



Dr. Andrea Cortés, DDS

- 2004 – 2008** Dentistry, Universidad El Bosque, Bogotá, Colombia
- 2007** Internship, Department of Cariology and Endodontics, Copenhagen University, Copenhagen, Denmark
- since 2009** Associated Instructor, Caries Research Unit UNICA, Universidad El Bosque, Bogotá, Colombia
- since 2009** Specialization in Pediatric Dentistry, Universidad El Bosque, Bogotá, Colombia

Prof. Dr. William J Davis, DDS, MS, MAGD

- 1970 DDS, Marquette University, Milwaukee, WI, USA
- 1970 – 1972 United States Navy, Brooklyn, NY, USA
- 1972 – 1974 Certificate in Prosthodontics, Memorial Sloan Kettering Cancer Center, New York, NY, USA
- 1974 – 1978 Assistant Professor, University of Michigan, School of Dentistry, Ann Arbor, MI, USA
- 1977 MS, Prosthodontics, University of Michigan, Ann Arbor, MI, USA
- 1978 – 1983 Associate Professor, Medical College of Ohio, School of Dentistry, Toledo, OH, USA
- 1978 – 2006 Director, General Practice Residency Program, Medical College of Ohio, Toledo, OH, USA
- 1981 – 2006 Visiting Associate Faculty, L.D. Pankey Institute for Advanced Dental Education, Miami, FL, USA
- 1983 – 1997 Professor & Chair, Department of Dentistry, Medical College of Ohio, Toledo, OH, USA
- 1988 MAGD, Master in General Dentistry, Academy of General Dentistry
- since 1997 Professor & Director, Division of Dentistry/Otolaryngology, Medical University of Ohio (former Medical College of Ohio), Toledo, OH, USA
- since 2004 Associate Dean, Continuing Medical Education, Medical University of Ohio, Toledo, OH, USA

Prof. Dr. med. dent. Christof Dörfer

- 1980 – 1985 Dentistry, Ruprecht-Karls-Universität, Heidelberg, Germany
- 1986 – 1993 Scientific Assistant, Ruprecht-Karls-Universität, Heidelberg, Germany
- 1993 – 2006 Professor, Senior physician, Department of Restorative Dentistry, Ruprecht-Karls-Universität, Heidelberg, Germany
- 1993 – 1998 Research Fellowships, University of Minnesota, Minneapolis, MN, USA
- since 2006 Professor and Chair, Department of Operative Dentistry and Periodontology, Christian-Albrechts-Universität, Kiel, Germany
- since 2009 Responsible Speaker “Dentistry”, German Network for Health Services Research



Authors



Prof. Dr. Sillas Duarte, PhD

- 1991 – 1991 Dentistry, Universidade Estadual Paulista (UNESP), Campus Araraquara, Araraquara, SP, Brazil
- 1995 – 2002 Associate Professor, Department of Operative Dentistry, Clinic of Restorative Dentistry, Universidade Estadual Paulista (UNESP), Campus Araraquara, Araraquara, SP, Brazil
- 2002 – 2004 Visiting Associate Professor, Department of Operative Dentistry, Clinic of Restorative Dentistry, University of Minnesota, MN, USA
- 2004 – 2007 Associate Professor, Department of Operative Dentistry, Clinic of Restorative Dentistry, Universidade Estadual Paulista (UNESP), Campus Araraquara, Araraquara, SP, Brazil
- 2007 – 2010 Associate Professor, Department of Comprehensive Care, Dental School, Case Western Reserve University, Cleveland, OH, USA
- since 2010 Associate Professor, Division of Restorative Science, Herman Ostrow School of Dentistry, University of Southern California (USC), Los Angeles, CA, USA



Dr. med. dent. Johannes Ebert

- 1982 – 1988 Dentistry, University of Erlangen-Nuremberg, Erlangen, Germany
- 1988 Certificate as a dentist (Approbation)
- since 1988 Assistant Professor, University of Erlangen-Nuremberg, Erlangen, Germany
- 1989 Doctoral degree, Dr. med. dent.
- 1989 – 1990 Dentist within the German Army
- since 1999 Associate Professor, University of Erlangen-Nuremberg, Erlangen, Germany

Maria Edwrigens Aparecida de Lima Ferreira

- 2007 – 2010 Graduate at Dental School, Universidade do Estado do Rio de Janeiro (UERJ), Rio de Janeiro, RJ, Brazil

Amely Eckstein

- since 2005 Dentistry, Georg-August-Universität, Göttingen, Germany

Dr. med. dent. Susanne Effenberger

- 1993 – 1999 Dentistry, Georg-August-Universität, Göttingen, Germany
- 1999 – 2005 Assistant Professor, Department of Restorative and Preventive Dentistry, University of Hamburg, PhD, University of Hamburg, Hamburg, Germany
- 2005 Assistant Professor, Department of Restorative Dentistry, CVK, Charité – Universitätsmedizin Berlin, Berlin, Germany
- 2006 – 2008 Professional Service Manager, Education/Scientific Affairs, DMG, Hamburg, Germany
- since 2008 Manager Clinical Research, Scientific Affairs, DMG, Hamburg, Germany



Prof. Dr. Kim Ekstrand, DDS, PhD

- 1978 – 1983 Dentistry, University of Copenhagen, Copenhagen, Denmark
- 1985 – 1988 PhD in Dentistry, University of Copenhagen, Copenhagen, Denmark
- since 1992 Associate Professor, Dental School, University of Copenhagen, Copenhagen, Denmark
- 1985 – 2002 Private Practice, Copenhagen, Denmark
- 1995 Visiting Professor, Guy's Hospital, London, United Kingdom
- 2002 – 2003 Visiting Professor, Dundee Dental Hospital, Dundee, United Kingdom




Prof. Dr. Jorge Faber, MSc, PhD

- 1984 – 1989 DDS, Universidade de Brasília (UnB), Brasília, DF, Brazil
- 1994 MSc in Orthodontics, Universidade Federal do Rio de Janeiro (UFRJ), Rio de Janeiro, RJ, Brazil
- 2003 PhD, Biology/Morphology, Universidade de Brasília (UnB), Brasília, DF, Brazil
- since 2008 Professor of Evidence Based Dentistry, Universidade de Brasília (UnB), Brasília, DF, Brazil
- since 2007 Editor in Chief of the Dental Press Journal of Orthodontics



Dr. Matthew D. Finkelman

- 2000 – 2004 Graduate Student, Department of Statistics, Stanford University, Palo Alto, CA, USA
- 2004 – 2005 Research Scientist I, CTB/McGraw-Hill, Monterey, CA, USA
- 2006 – 2007 Psychometrician I, Measured Progress, Inc., Dover, NH, USA
- 2007 – 2008 Research Fellow, Harvard School of Public Health, Boston, MA, USA
- since 2008 Assistant Professor, Tufts University, School of Dental Medicine, Boston, MA, USA



Dr. Esra Firat, PhD

- 1999 – 2004 Graduated in Dentistry, Hacettepe University, School of Dentistry, Ankara, Turkey
- 2004 – 2009 PhD programme, Department of Restorative Dentistry, Hacettepe University, School of Dentistry, Ankara, Turkey
- 2007 Visiting Research assistant, Aachen Dental Laser Centre (AALZ), Aachen, Germany



Authors




Prof. Dr. Marcio Garcia dos Santos, DDS, MSc, PhD

- 1990 – 1995 Dentistry, Universidade de São Paulo (USP), São Paulo, SP, Brazil
- 2000 MSc in Restorative Dentistry, Universidade de São Paulo (USP), São Paulo, SP, Brazil
- 2004 PhD in Restorative Dentistry, Universidade de São Paulo (USP), São Paulo, SP, Brazil
- 2004 – 2010 Professor, Fundação para o Desenvolvimento Científico e Tecnológico da Odontologia (FUNDECTO), Universidade de São Paulo (USP), São Paulo, SP, Brazil
- 1996 – 2010 Private Practice, São Paulo, SP, Brazil
- since 2010 Int. Product Manager, BEGO Implant Systems GmbH, Bremen, Germany



Prof. Dr. Guilherme Martinelli Garone, MSc

- 1992 – 1997 Dentistry, Universidade Cidade de São Paulo (UNICID), São Paulo, SP, Brazil
- 2001 – 2003 Orthodontics, Universidade de São Paulo (USP), São Paulo, SP, Brazil
- 2001 – 2003 MSc in Restorative Dentistry, Universidade de São Paulo (USP), São Paulo, SP, Brazil
- since 2000 Assistant Professor, Department of Restorative Dentistry, Universidade Cidade de São Paulo (UNICID), São Paulo, SP, Brazil
- since 1998 Private Practice, São Paulo, SP, Brazil



Dr. Juliana Gomez, DDS

- 1994 – 1998 Dentistry, Universidad El Bosque, Bogotá, Colombia
- 2001 – 2005 Specialization in Pediatric Dentistry, Université Paris V René, Paris, France
- 2001 – 2003 Certificate of Pediatric Stomatology, Hôpital Robert Debré, Paris, France
- 2010 PhD Candidate, University of Manchester, Manchester, United Kingdom



Dr. Boley J Greenwood, DDS

- 2000 – 2002 BA (Russian), Brigham Young University, Provo, UT, USA
- 2002 – 2006 DDS, University of Michigan, Ann Arbor, MI, USA
- 2006 UM Finalist Francis B. Vedder Award (Excellence in Crown & Bridge Work), University of Michigan, Ann Arbor, MI, USA
- 2006 – 2008 General Dentist, American Fork, UT, USA
- 2008 – 2009 General Dentist, Buffalo, NY, USA
- since 2009 Residency in Pediatric Dentistry, University of Toledo, Toledo, OH, USA

Prof. Dr. Sevil Gurgan, PhD

- 1975 – 1980 Dentistry, Hacettepe University, School of Dentistry, Ankara, Turkey
- 1985 PhD, Department of Restorative Dentistry, Hacettepe University, School of Dentistry, Ankara, Turkey
- 1988 – 1995 Associate Professor, Department of Restorative Dentistry, Hacettepe University, School of Dentistry, Ankara, Turkey
- since 1995 Professor, Department of Restorative Dentistry, Hacettepe University, School of Dentistry, Ankara, Turkey
- 1995 Visiting Professor, New York University, School of Dentistry, New York, NY, USA
- 2005 Visiting Professor, Tufts University, School of Dentistry, Boston, MA, USA
- since 2004 Head of the Department of Restorative Dentistry, Hacettepe University, School of Dentistry, Ankara, Turkey
- since 2008 Vice president of Hacettepe University, Ankara, Turkey



Prof. Dr. Leandro Augusto Hilgert, MSc, PhD

- 1999 – 2003 Dentistry, Universidade de Passo Fundo (UPF), Passo Fundo, SC, Brazil
- 2004 – 2005 Certificate in Operative Dentistry, Universidade Federal de Santa Catarina (UFSC), Florianópolis, SC, Brazil
- 2004 – 2006 MSc, Universidade Federal de Santa Catarina (UFSC), Florianópolis, SC, Brazil
- 2006 – 2009 PhD, Universidade Federal de Santa Catarina (UFSC), Florianópolis, SC, Brazil
Research Fellowship, Ludwig-Maximilians-Universität, Munich, Germany
- since 2009 Assistant Professor of Operative Dentistry, Universidade de Brasília (UnB), Brasília, DF, Brazil




Prof. Dr. Vinicius di Hipólito, DDS, MSc, PHD

- 1997 – 2001 Dentistry, Universidade Estadual de Campinas (UNICAMP), Piracicaba, SP, Brazil
- 2003 – 2009 MSc, PhD in Dental Materials, Universidade Estadual de Campinas (UNICAMP), Piracicaba, SP, Brazil
- since 2009 Professor, Clinic of Primary Care, Universidade dos Bandeirantes (UNIBAN), São Paulo, SP, Brazil
- since 2009 Researcher, Study group “Dentistry”, Universidade dos Bandeirantes (UNIBAN), São Paulo, SP, Brazil



Dr. Sidika Aynur Horuztepe, DDS

- 2003 – 2008 Graduated in Dentistry, Hacettepe University, School of Dentistry, Ankara, Turkey
- since 2009 PhD Programme, Department of Restorative Dentistry, Hacettepe University, School of Dentistry, Ankara, Turkey
- since 2009 Research assistant, Department of Restorative Dentistry, Hacettepe University, School of Dentistry, Ankara, Turkey



Authors




Dr. rer. nat. Klaus Jung

- 1999 – 2003 Statistics and Biology, University of Dortmund, Dortmund, Germany
- 2004 – 2006 Graduate school “Statistical Modelling”, University of Dortmund, Dortmund, Germany
- 2006 Dr. rer. nat. (Ph.D.), University of Dortmund, Dortmund, Germany
- 2006 – 2007 Postdoctoral Research Fellow, Medical Proteom Center, Ruhr-Universität Bochum, Bochum, Germany
- since 2007 Postdoctoral Research Fellow, Department of Medical Statistics, Georg-August-Universität, Göttingen, Germany

Jasper Keltsch

- 2004 – 2010 Dentistry, Christian-Albrechts-Universität, Kiel, Germany



Prof. Dr. med. dent. Andrej M. Kielbassa

- 1984 – 1989 Dentistry, Philipps-Universität, Marburg, Germany
- 1990 PhD, Philipps-Universität, Marburg, Germany
- 1998 Habilitation, Albert-Ludwigs-Universität, Freiburg, Germany
- 1990 Private Practice
- 1990 – 1993 Assistant Professor, Department of Pediatric Dentistry and Operative Dentistry, Philipps-Universität, Marburg, Germany
- 1993 – 1999 Senior Physician, Department of Operative Dentistry, Albert-Ludwigs-Universität, Freiburg, Germany
- since 2000 Director, Department of Operative Dentistry and Periodontology, Charité – Universitätsmedizin Berlin, Berlin, Germany

Eunyoung Kim

- 2002 – 2007 Dentistry, Pusan National University, Pusan, Korea
- 2008 – 2009 Internship, Pusan National University Hospital, Pusan, Korea
- since 2009 Residency, Department of Pediatric Dentistry, Pusan National University Hospital, Pusan, Korea
- since 2009 Master’s course, Dentistry, Pusan National University, Pusan, Korea



Prof. Dr. Shin Kim

- 1973 – 1979 Dentistry, Seoul National University, Seoul, Korea
- 1980 – 1982 Intern & Residency, Pediatric Dentistry, Seoul National University Hospital, Seoul, Korea
- 1985 – 1989 PhD, Pediatric Dentistry, Seoul National University, Seoul, Korea
- since 1985 Professor & Chair, Pediatric Dentistry, Pusan National University, Pusan, Korea
- 1999 – 2001 Director, Dental Hospital, Pusan National University, Pusan, Korea
- 2001 – 2003 Dean, College of Dentistry, Pusan National University, Pusan, Korea
- 2002 – 2006 Director, Scientific Affairs, Korean Academy of Pediatric Dentistry (KAPD)
- since 2008 Editorial Board, International Academy of Pediatric Dentistry (IAPD)
- since 2010 President, Korean Academy of Pediatric Dentistry (KAPD)

PD Dr. med. dent. Michael Knösel

- 1996 – 2001 Dentistry, Georg-August-Universität, Göttingen, Germany
- 2002 Private Practice, Eschwege, Germany
- since 2002 Assistant Professor, Department of Orthodontics, Georg-August-Universität, Göttingen, Germany
- 2003 Ph.D. (Dr. med. dent.), Georg-August-Universität, Göttingen, Germany
- 2006 Certificate of Specialist in Orthodontics, Georg-August-Universität, Göttingen, Germany
- since 2009 Research Fellowship, Aristotle University, Department of Orthodontics, Thessaloniki, Greece
- 2009 Habilitation, Venia legendi in Orthodontics, Georg-August-Universität, Göttingen, Germany

Dr. Juan Sebastian Lara, DDS

- 2003 – 2008 Dentistry, Universidad El Bosque, Bogotá, Colombia
- 2007 Internship, Department of Cariology and Endodontics, University of Copenhagen, Copenhagen, Denmark
- since 2009 Associated Instructor, Caries Research Unit UNICA, Universidad El Bosque, Bogotá, Colombia
- since 2010 “Young Researcher” for COLCIENCIAS, Caries Research Unit UNICA, Universidad El Bosque, Bogotá, Colombia

Marie-Christien Lawrenz

- 2001 – 2007 Dentistry, University of Hamburg, Hamburg, Germany
- 2007 – 2009 Assistant Dentist, Hamburg, Germany
- since 2010 Private Practice, Hamburg, Germany



Authors



PD Dr. Ing. Ulrich Lohbauer

- 1991 – 1998 Materials Science, Graduate Engineer, University of Erlangen-Nuremberg, Erlangen, Germany
- 1998 – 2003 Assistant Professor, Dental Clinic 1, University of Erlangen-Nuremberg, Erlangen, Germany
- 2003 PhD, University of Erlangen-Nuremberg, Erlangen, Germany
- since 2003 Director, Material Science, University of Erlangen-Nuremberg, Erlangen, Germany
- 2003 – 2004 Research Fellowship, Imperial College, London, United Kingdom
- 2006 Research Fellowship, University of Athens, Athens, Greece
- 2007 Habilitation, University of Erlangen-Nuremberg, Erlangen, Germany
- 2007 Academic Counsel, University of Erlangen-Nuremberg, Erlangen, Germany




Dr. rer. nat. Dierk Lübbers

- 1983 – 1989 Chemistry, University of Hamburg, Hamburg, Germany
- 1989 – 1992 PhD, Institute of Technical and Macromolecular Chemistry, University of Hamburg, Hamburg, Germany
- 1992 – 1997 Manager R&D Impression Materials and Adhesives, DMG, Hamburg, Germany
- 1998 – 1999 Manager R&D Cements, Coltène Whaledent AG, Altstätten, Switzerland
- 1999 – 2007 Manager R&D Europe, Coltène Whaledent AG, Altstätten, Switzerland
- since 2007 Manager Scientific Affairs, DMG, Hamburg, Germany



Luciana Marcondes Sarmiento Torres, DDS

- 2003 – 2006 Dentistry, Universidade Santa Cecília (UNISANTA), Santos, SP, Brazil
- since 2009 Graduated Student, Department of Restorative Dentistry, Universidade Estadual Paulista (UNESP), São José dos Campos, SP, Brazil



Prof. Dr. Stefania Martignon, PhD

- 1985 – 1990 Dentistry, Universidad Javeriana, Bogotá, Colombia
- 1993 – 1996 Specialisation in Pediatric Dentistry, Universidad El Bosque, Bogotá, Colombia
- 1997 – 2000 Specialisation Academic Teaching, Universidad El Bosque, Bogotá, Colombia
- 2001 – 2005 PhD in Dentistry, University of Copenhagen, Copenhagen, Denmark
- since 2006 Associate Professor, Director Caries Research Unit UNICA, Universidad El Bosque, Bogotá, Colombia
- since 2003 Member of the ICDAS Comitee

OA PD Dr. med. dent. Hendrik Meyer-Lückel, MPH

- 1992 – 1997 Dentistry, Justus-Liebig-Universität, Gießen, Germany
- 1997 – 1998 Assistant Professor, Department of Periodontology, Justus-Liebig-Universität, Gießen, Germany
- 1999 – 2000 Private Practice, Wetzlar, Germany
- 2000 PhD, Albert-Ludwigs-Universität, Freiburg, Germany
- 2000 – 2008 Assistant Professor/Senior Physician (from 2001), Department of Operative Dentistry and Periodontology, Charité – Universitätsmedizin Berlin, Berlin, Germany
- 2008 Habilitation, Charité – Universitätsmedizin Berlin, Berlin, Germany
- since 2008 Associate Professor, Department of Operative Dentistry and Periodontology, Christian-Albrechts-Universität, Kiel, Germany
- 2009 Master of Public Health (MPH), Charité - Berlin School of Public Health, Berlin, Germany



Dr. med. dent. Jan Müller

- 1998 – 2004 Dentistry, Freie Universität Berlin, Berlin, Germany
- 2005 PhD, Charité – Universitätsmedizin Berlin, Berlin, Germany
- since 2004 Assistant Professor, Department of Operative Dentistry and Periodontology, Charité – Universitätsmedizin Berlin, Berlin, Germany
- 2006 Winner VOCO Dental Challenge



Prof. Dr. Michael P Nedley, DDS

- 1989 DDS, Creighton University School of Dentistry, Omaha, NE, USA
- 1991 Certificate Specialization Pediatric Dentistry, University of Nebraska, Medical Center, Lincoln, NE, USA
- 1991 – 2003 Pediatric Practice, several locations in Wisconsin, Nebraska, Michigan, USA
- 1996 – 1999 Adjunct Lecturer, Department of Pediatric Dentistry, University of Michigan, Ann Arbor, MI, USA
- 1996 – 1998 Assistant Clinical Professor, Department of Pediatric Dentistry, University of Detroit Mercy, Detroit, MI, USA
- 1997 Diplomat, American Board of Pediatric Dentistry
- 1997 – 1999 Staff Dentist, Mott Children's Health Center, Flint, MI, USA
- 2001 – 2006 Pediatric Specialty Board Examiner
- since 2006 Assistant Professor & Director Pediatric Residency Program, Division of Dentistry/Otolaryngology, Medical University of Ohio, Toledo, OH, USA
- since 2003 Attending Faculty, Children's Hospital of Michigan, Detroit, MI, USA
- since 2004 Private Pediatric Practice, Rochester Hills, MI, USA




Authors



Derek A. Nobrega, BS

- 2002 – 2006 BS, Biology, Providence College, Providence, MA, USA
- 2006 – 2008 Research Assistant, Brown University, Providence, MA, USA
- since 2008 DMD Candidate, Tufts University, School of Dental Medicine, Boston, MA, USA



Dr. Joseph Palamara, PhD

- 1972 – 1976 BSc (Hons), Physics, Monash University, Melbourne, VIC, Australia
- 1977 Dip Ed, Physics, Monash University, Melbourne, VIC, Australia
- 1983 PhD, Physics, Monash University, Melbourne, VIC, Australia
- 1982 – 1983 Technical Officer, Department of Physics, Monash University, Melbourne, VIC, Australia
- 1984 – 1986 Research Officer, Department of Physics, Monash University, Melbourne, VIC, Australia
- 1987 – 1989 Senior Research Officer, Department of Physics, Monash University, Melbourne, VIC, Australia
- 1990 – 1993 Lecturer/Research Associate, Department of Physics, Monash University, Melbourne, VIC, Australia
- 1994 – 1996 Research Fellow, Department of Materials Engineering, Monash University, Melbourne, VIC, Australia
- 1995 Lecturer, Department of Applied Physics, RMIT, Melbourne, VIC, Australia
- 1994 – 1998 Research Associate, Royal Children's Hospital, Melbourne, VIC, Australia
- 2001 – 2003 Lecturer, Melbourne Dental School, The University of Melbourne, Melbourne, VIC, Australia
- since 2003 Senior Lecturer, Melbourne Dental School, The University of Melbourne, Melbourne, VIC, Australia



Dr. med. dent. Sebastian Paris

- 1998 – 2003 Dentistry, Charité Berlin, Berlin, Germany
- 2004 – 2008 Assistant Professor, Department of Operative Dentistry and Periodontology, Charité – Universitätsmedizin Berlin, Berlin, Germany
- 2005 PhD, Charité – Universitätsmedizin Berlin, Berlin, Germany
- since 2006 Research Fellowship, Deutsche Forschungsgemeinschaft, DFG
- since 2008 Assistant Professor/Lecturer, Department of Operative Dentistry and Periodontology, Christian-Albrechts-Universität, Kiel, Germany

Prof. Dr. Ronald D. Perry, DMD, MS, FACD, FICD, FADI

- 1982 – 1984 BS, History, Boston College, Boston, MA, USA
- 1984 – 1988 DMD, Dentistry, Henry M. Goldman Boston University, School of Graduate Dentistry, Boston, MA, USA
- 1999 MS, Tufts University, School of Dental Medicine, Boston, MA, USA
- 1990 – 1993 Research Associate, Clinical Instructor, Tufts University, School of Dental Medicine, Boston, MA, USA
- 1993 – 2000 Assistant Clinical Professor, Tufts University, School of Dental Medicine, Boston, MA, USA
- 1994 – 1998 Assistant Head of Operative Divisions, Tufts University, School of Dental Medicine, Boston, MA, USA
- since 1998 Director of the Gavel Center for Restorative Dental Research, Tufts University, School of Dental Medicine, Boston, MA, USA
- 2000 – 2008 Associate Clinical Professor, Department of Restorative Dentistry, Tufts University, School of Dental Medicine, Boston, MA, USA
- since 2008 IRB Human Investigational Committee Board Member, Blue Team, Tufts Medical Center, Boston, MA, USA
- since 2008 Clinical Professor, Prosthodontics and Operative Dentistry, Tufts University, School of Dental Medicine, Boston, MA, USA



Prof. Dr. Mathilde C. Peters, DMD, PhD, FADM, FICD

- 1969 – 1975 DMD, Faculty of Dentistry, Radboud University Nijmegen, Nijmegen, The Netherlands
- 1975 – 1994 Ass/Associate Professor, Faculty of Dentistry, Radboud University Nijmegen, Nijmegen, The Netherlands
- 1981 PhD Biomechanics, Medical Faculty, Radboud University Nijmegen, Nijmegen, The Netherlands
- 1982 Fulbright Visiting Research Scholar, Dentistry, University of Michigan, Ann Arbor, MI, USA
- 1988 Fellow (FADM), Academy of Dental Materials
- 1990 – 1991 Lasby Visiting Research Professor, MNDRCBB, University of Minnesota, Minneapolis, MN, USA
- 1994 – 1997 Professor and Chair of Restorative Dentistry, University of Adelaide, Adelaide, SA, Australia
- 1995 Fellow (FICD), International College of Dentists
- since 1997 Professor, Department of Cariology, Restorative Sciences and Endodontics, School of Dentistry, University of Michigan, Ann Arbor, MI, USA
- 2008 Hollenback Memorial Prize, Academy of Operative Dentistry
- 2008 – 2009 President, Cariology Research Group, International Association for Dental Research (IADR)
- since 2010 AADR Board of Directors, Member-at-Large, American Association for Dental Research, Alexandria, VA, USA



Authors



Dr. med. dent. Jin-Ho Phark

- 1998 – 2003 Dentistry, Humboldt-Universität Berlin, Berlin, Germany
- 2006 PhD, Charité – Universitätsmedizin Berlin, Berlin, Germany
- 2003 – 2006 Assistant Professor, Department of Operative Dentistry, CVK, Charité – Universitätsmedizin Berlin, Berlin, Germany
- 2006 – 2010 Associate Professor, Department of Comprehensive Care, Dental School, Case Western Reserve University, Cleveland, OH, USA
- since 2010 Assistant Professor, Division of Restorative Science, Herman Ostrow School of Dentistry, University of Southern California (USC), Los Angeles, CA, USA



Archana Rajan, BDS, MPH, DDS

- 1997 – 2002 BDS, Ambedkar Dental College and Hospital, Bangalore, India
- 2002 – 2003 Rotating Internship, Ambedkar Dental College and Hospital, Bangalore, India
- 2004 – 2006 MPH, Northern Illinois University, DeKalb, IL, USA
- 2007 – 2009 DDS, University of Michigan, Ann Arbor, MI, USA
- 2008 AADR Student Research Fellowship Award
- 2009 – 2010 General Practice Residency, University of Toledo Medical Center, Toledo, OH, USA
- since 2010 Graduate Orthodontic Program, University of Michigan, Ann Arbor, MI, USA



Prof. Dr. Carlos Rocha Gomes Torres, DDS, PhD

- 1992 – 1995 Dentistry, Universidade Estadual Paulista (UNESP), São José dos Campos, SP, Brazil
- 1996 – 2002 Private Practice, São Paulo, SP, Brazil
- 2002 PhD, Universidade Estadual Paulista (UNESP), São José dos Campos, SP, Brazil
- 2009 Visiting Professor, Clinic for Preventive Dentistry, Periodontology and Cariology, University of Zurich, Zurich, Switzerland
- since 2002 Assistant Professor, Department of Restorative Dentistry, Universidade Estadual Paulista (UNESP), São José dos Campos, SP, Brazil



Prof. Dr. med. dent. Ulrich Schiffner

- 1975 – 1980 Dentistry, PhD, University of Hamburg, Hamburg, Germany
- since 1982 Assistant Professor, Department of Restorative and Preventive Dentistry, University of Hamburg, PhD, University of Hamburg, Hamburg, Germany
- 1988 – 1992 Advisory Board, German Association for Operative Dentistry (DGZ, Secretary)
- since 2003 Director Section of Preventive Dentistry, Department of Restorative and Preventive Dentistry, University of Hamburg, PhD, University of Hamburg, Hamburg, Germany
- 2004 – 2008 President German Association of Pediatric Dentistry (DGK)

Dr. rer. nat. Hartmut Schneider

- 1971 – 1976 Physics, Karl-Marx-Universität, Leipzig, Germany
- 1976 – 1995 Assistant Professor, Section Bioscience, Department Cell Biology/Regulation, University of Leipzig, Leipzig, Germany
- 1982 PhD, Karl-Marx-Universität, Leipzig, Germany
- since 1995 Associate Professor, Department of Conservative Dentistry and Periodontology, University of Leipzig, Leipzig, Germany



Prof. Edward Werner Schubert, MSc

- 1984 – 1988 Dentistry, Universidade Federal de Santa Catarina (UFSC), Florianópolis, SC, Brazil
- 1995 – 1996 Specialisation in Esthetic Dentistry, Universidade Federal de Santa Catarina (UFSC), Florianópolis, SC, Brazil
- 2000 – 2002 Master of Science in Dentistry, Universidade Federal de Santa Catarina (UFSC), Florianópolis, SC, Brazil
- since 1999 Associate Professor, Dental School, Restorative Dentistry, Universidade da Região de Joinville (UNIVILLE), Joinville, SC, Brazil
- since 2001 Associate Professor, Dental School, High Complexity Clinic, Universidade da Região de Joinville (UNIVILLE), Joinville, SC, Brazil
- since 2007 Coordinator Extension Program “Sorria Vila da Glória”, Universidade da Região de Joinville (UNIVILLE), Joinville, SC, Brazil
- since 2009 Associate Professor, Dental School, Low Complexity Clinic, Universidade da Região de Joinville (UNIVILLE), Joinville, SC, Brazil



Maria Schuch

- 2003 – 2009 Dentistry, Freie Universität Berlin, Berlin, Germany
- since 2009 Doctoral Thesis, Department of Operative Dentistry and Periodontology, Christian-Albrechts-Universität, Kiel, Germany



Dr. med. dent. Andreas Schult

- 1977 – 1980 Professional training as Dental Technician, Hannover, Germany
- 1980 – 1986 Dental Technician, Hannover
- 1986 – 1991 Dentistry, University of Hamburg, Hamburg, Germany
- 1991 – 2004 PhD, Assistant Professor, Department of Restorative Dentistry and Periodontology, University of Hamburg, Hamburg, Germany
- since 2001 Partner of a joint private practice, Bad Bramstedt, Germany



Authors



Dr. Mariana Séllos, MSc

2001 – 2005 Dentistry, Universidade do Estado do Rio de Janeiro (UERJ), Rio de Janeiro, RJ, Brazil

2006 – 2007 Specialisation in Pediatric Dentistry, Universidade do Estado do Rio de Janeiro (UERJ), Rio de Janeiro, RJ, Brazil

2008 – 2010 Master of Science in Pediatric Dentistry, Universidade do Estado do Rio de Janeiro (UERJ), Rio de Janeiro, RJ, Brazil

since 2010 Private Practice, Rio de Janeiro, RJ, Brazil



Isabela Silva Gomes, DDS

2005 – 2008 Dentistry, Universidade Estadual Paulista (UNESP), São José dos Campos, SP, Brazil

since 2009 Graduated Student, Department of Restorative Dentistry, Universidade Estadual Paulista (UNESP), São José dos Campos, SP, Brazil



Prof. Rodrigo Simões de Oliveira, DDS

1999 – 2003 Dentistry, Universidade Severino Sombra (USS), Vassouras, RJ, Brazil

since 2005 Assistant Professor, Universidade Severino Sombra (USS), Vassouras, RJ, Brazil

since 2009 Graduated Student, Department of Restorative Dentistry, Universidade Estadual Paulista (UNESP), São José dos Campos, SP, Brazil



Beatriz Soares de Oliveira

2007 – 2010 Graduated Student, Dental School, Universidade do Estado do Rio de Janeiro (UERJ), Rio de Janeiro, RJ, Brazil



Nádia de Souza Ferreira, DDS

2005 – 2008 Dentistry, Universidade Estadual Paulista (UNESP), São José dos Campos, SP, Brazil

since 2009 Graduated Student, Department of Restorative Dentistry, Universidade Estadual Paulista (UNESP), São José dos Campos, SP, Brazil

Prof. Dr. Vera Ligia Vieira Mendes Soviero, MSc, PhD

- 1987 – 1991 Dentistry, Universidade do Estado do Rio de Janeiro (UERJ), Rio de Janeiro, RJ, Brazil
- 1994 – 1997 Master of Science in Pediatric Dentistry, Universidade Federal do Rio de Janeiro (UFRJ), Rio de Janeiro, RJ, Brazil
- 1997 – 1999 PhD in Pediatric Dentistry, Universidade Federal do Rio de Janeiro (UFRJ), Rio de Janeiro, RJ, Brazil
- 1997 – 1999 Assistant Professor, Dental School, Universidade Iguazu (UNIG), Nova Iguaçu, RJ, Brazil
- 1998 – 2006 Assistant Professor, Dental School, Universidade Estácio de Sá, Rio de Janeiro, RJ, Brazil
- since 1999 Associate Professor, Dental School, Universidade do Estado do Rio de Janeiro (UERJ), Rio de Janeiro, RJ, Brazil



Katja Spieler-Husfeld

- 1990 – 1993 Chemical Laboratory Assistant, Beiersdorf AG, Hamburg, Germany
- 1993 – 1998 Development Laboratory “tesa” labels/Adhesive tapes, Beiersdorf AG, Hamburg, Germany
- 1998 – 2000 Law Office/Notary Office Mueller-Schubert and Partner, Hamburg, Germany
- 2000 – 2002 Chemical Development, DMG, Hamburg, Germany
- 2002 – 2004 Technical Development (Scale up), DMG, Hamburg, Germany
- since 2004 Scientific Affairs, DMG, Hamburg, Germany



Prof. Dr. Christian H. Splieth

- 1985 – 1986 Dentistry, Georg-August-Universität, Göttingen, Germany
- 1986 – 1987 Dentistry and Oral Biochemistry, School of Dentistry, University of Leeds, Leeds, United Kingdom
- 1987 – 1989 Dentistry, Georg-August-Universität, Göttingen, Germany
- 1989 Dentistry, School of Dentistry, University of Minnesota, Minneapolis, MN, USA
- 1989 – 1990 Dentistry, Georg-August-Universität, Göttingen, Germany
- 1990 – 1993 Dentist, Private Practices, Duisburg, Northeim, Germany
- 1992 Dr. med. dent., Georg-August-Universität, Göttingen, Germany
- 1993 Assistant Professor, Department of Restorative Dentistry, Periodontology and Pediatric Dentistry, Ernst-Moritz-Arndt-Universität, Greifswald, Germany
- 1994 Visiting Professor, Pediatric Dentistry, University of California in San Francisco, San Francisco, CA, USA
- 2000 Habilitation, Ernst-Moritz-Arndt-Universität, Greifswald, Germany
- 2004 Professor for Pediatric Dentistry, Department of Operative Dentistry and Periodontology, Christian-Albrechts-Universität, Kiel, Germany
- since 2004 Professor and Chair Department of Preventive and Pediatric Dentistry, Ernst-Moritz-Arndt-Universität, Greifswald, Germany



Authors



Christin Staude

- 1997 – 2001 Dental Technician Education, Dullek Dental Laboratory, Güstrow, Germany
- 2001 Dental Technician, Dullek Dental Laboratory, Güstrow, Germany
- 2001 – 2006 Dental Technology, Graduate Engineer, University of Applied Sciences, Osnabrück, Germany
- Internship, Diploma Thesis, Amann Girrbach GmbH, Koblach, Austria
- since 2007 Scientific Affairs, DMG, Hamburg, Germany



Michael Stiebritz

- 1994 – 1998 Professional training as Chemist, Robert-Koch-Institute, Berlin, Germany
- 1998 Chemist, Robert-Koch-Institute, Berlin, Germany
- 1999 – 2000 Chemist, Robert-Koch-Institute, Berlin, Germany
- 2001 Chemist, Deutsche Industrie Service AG, Postdam, Germany
- 2002 – 2003 Technical assistant, Max-Planck-Institute for Molecular Plant Biology, Potsdam, Germany
- 2005 – 2008 Chemist, Department of Operative Dentistry and Periodontology, Charité – Universitätsmedizin Berlin, Berlin, Germany
- since 2008 Chemist, Department of Operative Dentistry and Periodontology, Christian-Albrechts-Universität, Kiel, Germany



Prof. Dr. Marisol Tellez, DDS, MPH, PhD

- 1993 – 1998 Dentistry, Universidad El Bosque, Bogotá, Colombia
- 2001 Pan American Health Organization, Division of Health Systems and Services Development, Washington, DC, USA
- 2001 Master of Public Health (MPH), University of Michigan, Ann Arbor, MI, USA
- 2003 GSI, Department, Department of Epidemiology, University of Michigan, Ann Arbor, MI, USA
- 2004 PhD, Epidemiological Sciences, University of Michigan, Ann Arbor, MI, USA
- 2003 – 2006 Research Associate, Detroit Center for Research on Oral Health Disparities, University of Michigan, Ann Arbor, MI, USA
- since 2006 Associate Professor, Caries Research Unit UNICA, Universidad El Bosque, Bogotá, Colombia
- since 2008 Academic Manager, Colgate Palmolive Bogotá, Colombia

Prof. Dr. Dr. Martin Tyas, PhD, DDSc

- 1977 PhD
- since 1984 Member of various scientific committees of the Australian Dental Association
- since 1984 Member International Association of Dental Research
- since 1985 Leader of the Australian Delegation of the International Organization for Standardization Technical Committee 106
- Consultant in Dental Material to the Australian Defence Force
- 1994 DSc
- 2001 – 2007 Former Member of Science Committee of the FDI World Dental Federation
- since 2002 Council Member of the Royal Australasian College of Dental Surgeons
- 2007 – 2009 Chairman of Science Committee of the FDI World Dental Federation
- since 2009 Professorial Fellow and Former Professor and Head of Restorative Dentistry, Melbourne Dental School, The University of Melbourne, Melbourne, VIC, Australia

